

Case Report

Congenital sideroblastic anemia of a Saudi child

Muneer H ALBagshi (1, 2), Somaya H Saloma (1), Hassan M Albagshi (1)

(1) Department of Hematology Oncology, Maternity and Children Hospital, Saudi Arabia

(2) Hereditary Blood Diseases Center-Al Ahsa, Saudi Arabia

ABSTRACT

Sideroblastic anemia is a heterogeneous group of disorders characterized by the presence of ring sideroblasts in the bone marrow, and has congenital and acquired forms. Congenital sideroblastic anemia is a rare condition, which is mostly X-linked, caused by mutations of delta-aminolevulinic acid synthase 2. We describe one case of congenital sideroblastic anemia, indicating an autosomal recessive inheritance, with its clinico-hematological profile. It is important to recognize this entity early in life as a significant percentage of cases respond to pyridoxine thus avoiding any long-term complications.

Keywords:

Anemia; Congenital; Sideroblastic anemia; Saudi Arabia.

INTRODUCTION

Sideroblastic anemia is a heterogeneous group of disorders characterized by anemia and the presence of ring sideroblasts in the bone marrow [1]. It is either acquired or congenital forms, but both are refractory to iron therapy. Acquired type has been

classified into idiopathic, secondary, and reversible groups. Congenital sideroblastic anemia is a rare condition with clinical and genetic heterogeneity. The most frequent form is X-linked, caused by mutations of delta-aminolevulinic acid synthase 2 (ALAS2) [2]. However, autosomal recessive, dominant, and mitochondrial pattern of inheritance have been documented. It is important to recognize this entity early in life as around 75% cases may respond to pyridoxine thus avoiding any long-term complications. We present a case of congenital sideroblastic anemia with their clinico-hematological profile.

CASE REPORT

Six years old Saudi boy presented with pallor since one month of life, after several red cell transfusions have been received. He was investigated along the line of bone marrow failure, but the patient lost follow up for five years. He appeared at the age of five and half years because of pallor without jaundice or change in urine color. He was treated with iron for suspected iron deficiency anemia without improvement for four months before hematology referral. He has G6PD deficiency.

Correspondence to:

Muneer H Albagshi

Pediatric Hematology Oncology Unit

Maternity And Children Hospital

Al Hassa, Saudi Arabia

Email: mbagshi@gmail.com

How to cite this article:

ALBagshi MH, Saloma SH, Albagshi HM.

Congenital Sideroblastic Anemia of Saudi Child.

Sudan J Paediatr 2017; 17(1):49-51

There was history of neonatal jaundice and. The parents are second-degree cousins. There are three siblings two girls are normal. There was a one-month-old male sibling presented with anemia received transfusion, but died of respiratory infection before investigations.

He was active alert, pale, unicteric, and not dysmorphic. The weight and height were appropriate for age. The skin, abdomen, musculoskeletal, and neurological examination were normal.

Investigations revealed the following: Hb 6.3 g/dl, RBC $3.1 \times 10^6/\mu\text{L}$, MCV 66 fl, MCH 22pg, MCHC 34 g/dl, platelets $243 \times 10^3/\mu\text{L}$ and reticulocytes 2.0%. Red cell morphology showed marked microcytosis, few red cell fragmentations, and mild anisocytosis. Serum iron 24 UM/L TIBC 55 UM/L, Ferritin 620ng/ml. Serum Folate 22 nmol/L and B12 1834 pmol/L. Hb electrophoresis was normal (Hb A1 97.6%, A2 2.4%). Normal blood gases and lactic acid. Hb H preparation was negative. Qualitative G6PD showed deficiency.

He was treated with red cell transfusion for three times, and later he was given iron therapy 5mg/kg/day for suspicious of iron deficiency anemia (IDA) without improvement and the hemoglobin was 6.5 gm/dl after three months of therapy. Bone Marrow examination showed normal cellularity, myeloid to erythroid ratio (M:E ratio) of 1.2:1 with normoblastic erythroid maturation figure 1. There was mild dyserythropoiesis. Myeloid and megakaryocytic series were within normal limits. Perls' stain showed increased iron stores with presence of ring sideroblasts in excess of 37.0% of the developing erythrocytes. ALAS2 gene mutation analysis was not available for the study and the parents refused to send sample abroad. The diagnosis of congenital sideroblastic anemia was made and he started on pyridoxine 40 mg P.O daily without change in his condition, thiamine was added and the hemoglobin stabilized between 8.2-8.5 gm/dl. He is thriving and transfusion independent for three years.

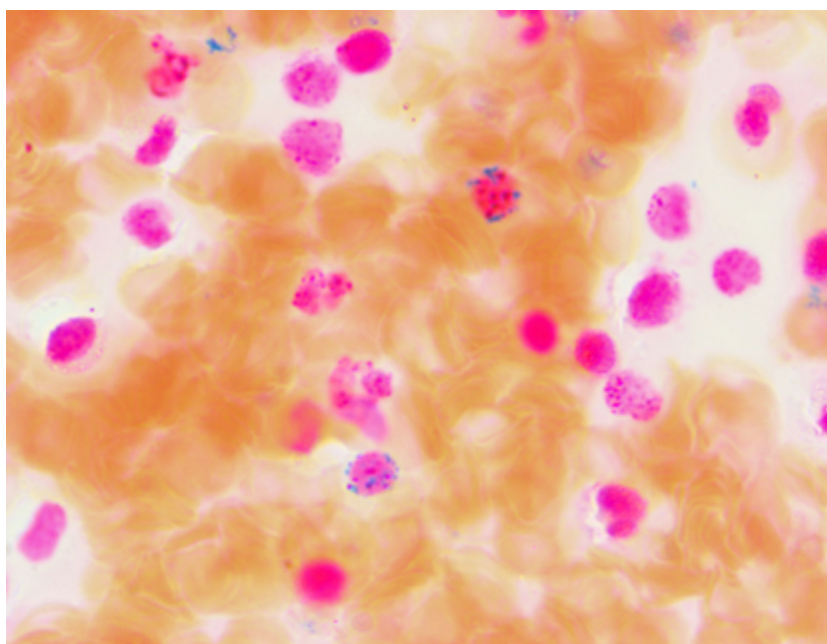


Figure 1 - Bone Marrow film showing the ring sideroblasts.

DISCUSSION

Cooley first reported congenital sideroblastic anemia in 1945 [3]. It is rare anemia and characterized by heterogeneous patterns of inheritance. The most

frequent form is X-linked sideroblastic anemia (XLSA), caused by mutations of ALAS2. It may rarely show autosomal dominant, recessive

inheritance of mitochondrial origin. The differential diagnosis includes several variants of myelodysplastic syndrome, with the absence of significant dysplasia in the myeloid series and or the megakaryocytes. Sideroblasts are found in the normal bone marrow nucleated red blood cell precursors (erythroblasts) with one or more iron-containing granules in the cytoplasm, with exaggeration when it form ring surrounds the nucleus [4]. These iron rings are in excess not utilized for hemoglobin synthesis, rather it act as a toxin, which either initiates or aggravates intracellular organelle damage finally resulting in ineffective erythropoiesis [5]. In our case the patient presented in early age and presumably his dead male sibling affected led us to think of autosomal recessive mode of inheritance of this sideroblastic anemia.

The importance of the presentation because of the prevalence of thalassemia and iron deficiency anemia as deferential diagnosis in our community. The presentation of microcytic anemia with the low reticulocyte count for the degree of anemia raised the possibility of beta thalassemia homozygous state and he was given transfusions, and at later presentation he was suspected to have IDA but he was refractory to it after three months of therapy.

The bone marrow examination showed erythroid hyperplasia, There is mild defective hemoglobinization of late normoblasts and vacuolation of some

erythroblasts with intact cytoplasmic margins, some vacuoles are surrounded by heavily stained granules (punctate basophilia) and abundant ring sideroblasts (37%) of the normoblasts by Perls' stain which is diagnostic for the sideroblastic anemia. Pearson' syndrome is autosomal recessive disorder was excluded in the patient as he has no neural defect or diabetes mellitus. Myelodysplastic syndrome was excluded, as the bone marrow did not show dysplasia in the blood cells lines.

Pyridoxine may improve anemia in pyridoxine responsive type around 75% of ALAS2 defects. Our patient responded partially to pyridoxine and the hemoglobin was maintained between 7.5-8.2gm/dl and he was thriving and transfusion independent.

Pediatricians need to be aware about microcytic hypochromic anemia in early age to keep beta thalassemia, alfa thalassemia, iron deficiency anemia with simple hemoglobin electrophoresis, Hb H preparation, serum iron studies, and if now diagnosis is reached then bone marrow examination with iron stain should be done.

CONCLUSION

The early detection and therapy of pyridoxine will prevent the chronic complication and eliminate the need for chronic transfusion. In selected cases, thiamine could be of help to stabilize the hemoglobin.

REFERENCES

1. Gupta SK, Rao S, Kar R, Tyage S, Pati HP. Congenital Sideroblastic Anemia: A report of two cases. *Indian J Pathol Microbiol* 2009; 52:424-6
2. Bottomley SS. Sideroblastic anemias. In: Greer JP, Foerster J, Lukens JN, Rodgers GM, Paraskevas F, Glader B, editors. *Wintrobe's Clinical Hematology*. 11thed. Philadelphia: Lippincott Williams and Wilkins; 2004. p.1011-33.
3. Camaschella C. Recent advances in the understanding of inherited sideroblastic anaemia. *Br J Haematol* 2008; 143:27-38.
4. Fleming MD. Congenital sideroblastic anemias: iron and heme lost in mitochondrial translation. *Hematology Am Soc Hematol Educ Program* 2011; 2011:525.
5. Nusbaum NJ. Concise review. Genetic basis for sideroblastic anemias. *Am J Hematol* 1991; 37: 41-44.