

Original Article

Interventional Catheterization for Congenital Heart Disease: Experience at the Sudan Heart Centre

Sulafa KM Ali *

* University of Khartoum, Faculty of Medicine, Department of Paediatrics and Child Health PO Box 102 AND the Department of Paediatric Cardiology, Sudan Heart Center. PO Box 11917, Khartoum Erkeiteh, Sudan.

Email: sulafakhalid2000@yahoo.com

ABSTRACT

Interventional catheterization for congenital heart disease is a rapidly evolving speciality which had been introduced in Sudan recently. This retrospective review aims at presenting the experience from Sudan.

Patients and Methods:

All patients who underwent interventional catheterization for congenital heart disease at the Sudan Heart Center in the period from July 2004 to July 2009 that were done by the author were included in this retrospective review.

Results:

In the study period 347 patients underwent cardiac catheterization. Of these 281 (81%) were diagnostic and 66 (19%) were interventional. For interventional procedures the age ranged from 12 hours to 43 years with a mean of 10 years. Procedures included balloon dilatation of the pulmonary valve (20), patent ductus arteriosus device closure (36), Atrial septal defect device closure (3) and balloon atrial septostomy (6) and balloon dilatation of the aortic valve (1). All patients with patent ductus arteriosus and ASD had successful device closure. Of those who had pulmonary valve dilatation 15 had severe stenosis that

was successfully dilated and in 5 patients dilatation was not possible: two infants had critical stenosis and 3 were Noonan's syndrome. Six patients underwent balloon septostomy (12 hours- 3 months old): all of them had acceptable size atrial septal defect.

Major obstacles included late referral, the lack of regular supply of catheters and occluders and the deficiency of pre and post catheterization intensive care setup.

Conclusion:

This initial report shows that results of interventional catheterization for CHD in Sudan are encouraging. Early referrals, improving intensive care setup and continuous supply of catheters at affordable cost are needed to consolidate this program.

Key words: Congenital Heart Disease, interventional catheterization, Sudan Heart Centre

Introduction:

In the last 50 years there had been tremendous advances in the field of congenital heart disease (CHD) diagnosis and management. Revolution of the techniques of 2-dimensional and 3-dimensional echocardiography allowed precise diagnosis of CHD, improvement of the surgical techniques including intra operative and post operative management lead to survival of patients with complex CHD. The

role of cardiac catheterization (CC) shifted from diagnostic to interventional purposes. Rashkind atrial septostomy was first reported in 1962 and opened the gate for other interventions (1). In 1982 Kan first reported the successful dilatation of pulmonary valve stenosis. (2). Soon after this aortic valve dilatation and dilatation of coarctation became widely used. In recent years closure of congenital defects like patent ductus arteriosus (PDA), atrial septal defects (ASD) and ventricular septal defects became well established.

Patients and Methods:

All patients who underwent interventional CC for CHD at the Sudan Heart Centre from July 2004 to November 2009 were included in this retrospective review. Patients were evaluated clinically and by a complete 2-dimensional echocardiography. Selection for intervention was made according to the echocardiographic anatomy of the lesion. CC was done

under sedation for stable patients and under general anesthesia for hemodynamically compromised patients and for those undergoing ASD closure. Patients who were discharged after 12- 24 hours unless there are indications for longer admission. Follow up by clinical and echocardiographic examination every 26- month was arranged.

Results:

In the study period 347 patients underwent cardiac catheterization. Of these 281 (81%) were diagnostic and 65 (19%) were interventional.

Interventional Catheterization:

The age ranged from 12 hours to 43 years with a mean of 10 years. Table 1 summarizes the procedures done and their outcome. The patients were followed for 636- months.

1. Pulmonary valve dilatation (PVD):

Twenty patients underwent PVD. Age ranged from 2 months to 43 years and weight 3- 70 kg.

Table 1. Interventional catheterization procedures done at the Sudan Heart Centre by the author from July 2004-November 2009 and their outcome. Procedures:

Procedure	No (%)	Outcome (Success/Failure)	Complications	Follow up
PDA closure	36	36/0	Non	No residual shunt, no stenosis of left pulmonary artery or aorta.
Pulmonary valve dilatation	20	15/5	Non	Pressure gradient abolished in 15, 3 Noonan syndrome and 2 young infants referred for surgery
Balloon atrial septostomy	8	6/0	Vascular injury (1)	2 deaths (respiratory and renal failure 2 and 3 month old infants), 4 awaiting surgery
Atrial septal defect closure	3	3/0	Non	Successful occlusion
Aortic valve dilatation	1	1/0	Non	Gradient dropped by 50%

Three patient were syndromic with short stature and features suggestive of Noonan's syndrome. A single balloon was used in 15 and two balloon method in 5 patients.

The echo and cath gradients correlated well and ranged between 50 - 120 mmHg. In all patients dilatation was successful except in 5. Two infants (2 and 3 months) had critical stenosis and needed very small wires which were not available. Another 3 patients had features of Noonan's syndrome where dilatation did not drop the gradient .One of them had supravalve stenosis. All the five were referred to the surgeon.

2. PDA occlusion:

Thirty six patients underwent PDA device closure. The patients, age ranged between 18 months to 15 years and the weight 9- 30 kg.PDA size ranged between 2.57- mm. Amplatzer® PDA occluder (AGA-USA) was used in 12 patients and Balmedics (China) in the others. The devices were comparable and successfully occluded the defect with no residual in all patients. (Fig 1)

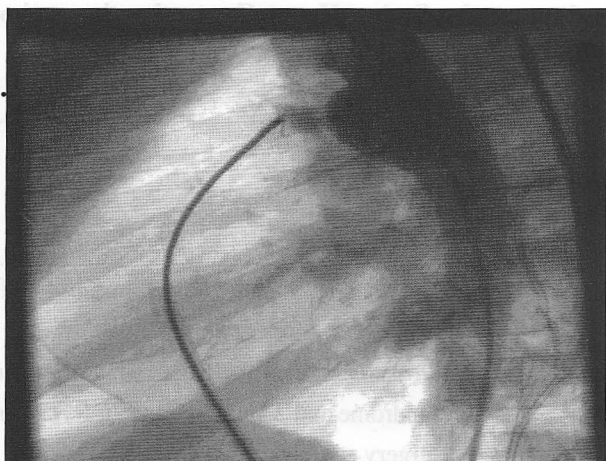


Figure 1. Lateral view aortogram showing the PDA device (arrow) well fitted -not yet deployed- and no residual flow seen from aorta to pulmonary artery.

Balloon Atrial Septostomy (BAS):

Six patients: (2 were 12 and 24 hours old, 2 were 7 and 10 days old and 2 were 2 and 3 months old) had

BAS. All had transposition of the great arteries with intact interventricular septum. Three procedure was done through the umbilical vein and 3 through the femoral vein. (Fig 3). One procedure (at 12 hours of age) was done in the nursery (Soba University Hospital) under echocardiographic guidance. Two patients (2 and 3 months old) died 5 and 7 days after the procedure due to aspiration pneumonia in one and acute renal failure in the other. One patient developed leg ischemia needing streptokinase infusion.

Discussion:

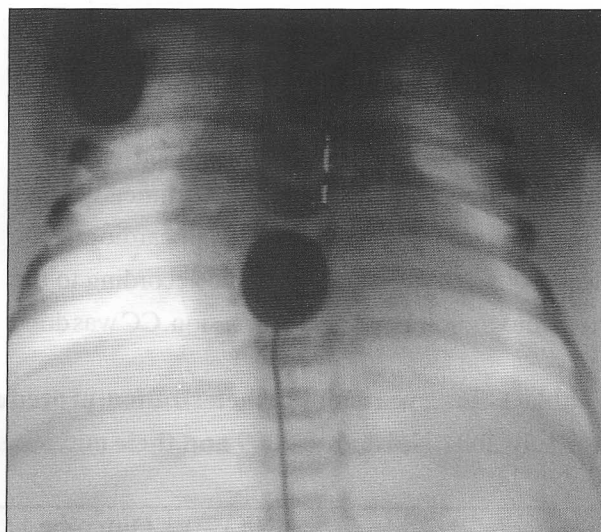


Figure 2. Anteroposterior fluoroscopic view showing the atrial septostomy balloon catheter pulled from left to right atrium through the patent fossa ovalis.

Interventional CC needs well equipped laboratories and highly trained personnel. The catheters and devices used are expensive and not readily available in Sudan as it is mostly produced in Western countries. Another limiting factor is the need for different sizes during a single procedure which necessitates that the centre supplies at least 23- devices /balloon catheters per procedure. The advantages of interventional catheterization over surgical treatment are obvious: less need for general

anesthesia, the absence of surgical scar, avoidance of cardio-pulmonary bypass in case of PVD, VSD, AVD and ASD, less duration of admission and much less discomfort and complications. Public awareness about these advantages is increasing, however in terms of cost CC procedures and surgery are more or less the same. This situation may change in the coming few years as more manufacturers invest in catheters and devices and this had already resulted in launching new cheaper devices. Our results for PVD for older infants and children are comparable with other centers (3). For young infants and neonates our setup needs many refinements particularly the availability of neonatal and paediatric intensive care unit and the life-saving drug: prostaglandin E1. We attempted to do balloon dilatation in critically ill infants and found that results are not encouraging. The same limiting factors apply to the poor outcome of our patients with transposition of the great arteries with intact interventricular septum, as these patients need early intervention in the first day of life. Paediatricians and family physicians need to identify these babies promptly and refer them early to assure a good outcome. As for PDA and ASD device closure our results are comparable to other centers with no complications reported.(4) Although it is technically demanding, muscular VSD closure has been well established but closure of the more common perimembraneous VSD is not as established yet. Soon after launching the perimembraneous VSD occluder there were many reports about immediate and short term occurrence of complete atrioventricular block sometimes needing permanent pacing (5) which urged many operators to stop doing these procedures. In our opinion VSD catheter closure is not a priority at the moment because of the technical difficulties and liability for complications like device embolization. With the rapidly advancing technology of occluding

devices we anticipate that more user-friendly devices will be produced.

One of the major factors that contributed to the steady development of our CC program is inviting experienced cardiologists from abroad which consolidated the local experience technically and financially by supplying free devices for many patients. Special acknowledgement must be made to Dr.Mohammed Tawfig Numan from Hamad Medical corporation –Doha-Qatar for his great efforts in this regards.

In conclusion we presented the growing experience of our centre in interventional CC, in our opinion we need to augment the pre and post procedure intensive care setup and refer patients early in order to have a better outcome for young infants.

References:

- 1.Waldhausen JA, Boruchow I, Miller WW,Rashkind WJ. *Transposition of the great arteries with ventricular septal defect.Palliation by atrial septostomy and pulmonary artery banding.Circulation. 1969;39(Suppl 1):I21521-.*
- 2.Kan JSz, White RI Jr, Mitchell SE, Gardner TJ2.*Percutaneous balloon valvuloplasty: a new method for treating congenital pulmonary 1982;307:5402-.N Engl J Med.*
- 3.Wilson ADRao PS, Galal O, Patnana M, Buck SH3.*Results of three to 10 year follow up of balloon dilatation of the pulmonary valve. Heart.1998;80:5915-.*
4. Atiq M, Aslam N, Kazmi KA. *Transcatheter closure of small-to-large patent ductus arteriosus with different devices: queries and challenges. J Invasive Cardiol. 2007;19:2958-*
- 5.Carminati M, Butera G, Chessa M, De Giovanni J, Fisher G, Gewillig M, Peuster M, Piechaud JF, Santoro G, Sievert H, Spadoni I, Walsh K; *for the Investigators of the European VSD Registry. Transcatheter closure of congenital ventricular septal defects: results of the European Registry Eur Heart J. 2007;28:23618-. Epub 2007*