

## Case report

# Encephalopathy with Continuous Spikes and Waves during Sleep, Landau-Kleffner Syndrome, and Atypical Benign Partial Epilepsy (Pseudo-Lennox Syndrome): Clinical and EEG Manifestations of Three Children and Review of the Literature

Imad Yassin Saadeldinl, Mohammed S. Zayed 1

(1) Armed Forces Hospital, Southern Region, Paediatric Department, Khamis Mushayt, Saudi Arabia

## ABSTRACT

Encephalopathy with continuous spikes and waves during sleep and Landau-Kleffner syndrome are two rare epileptic encephalopathies of childhood. Atypical benign partial epilepsy or pseudo-Lennox syndrome is characterized by multiple types of seizures and typical electroencephalogram (EEG) in developmentally normal children. The authors describe the electroclinical features and management options of 3 paediatric patients, one with encephalopathy with continuous spikes and waves during sleep, the second with Landau-Kleffner syndrome, and the third with atypical benign partial epilepsy, and demonstrate the possible common pathogenesis of the three syndromes.

Key words: Encephalopathy with continuous spikes and waves during sleep; Landau-Kleffner syndrome; atypical benign partial epilepsy; pseudo-Lennox syndrome; EEG

## Introduction

Encephalopathy with continuous spikes and waves during sleep or electrical status epilepticus during sleep is a childhood encephalopathy characterized by the following:1,2

1. Seizures, usually with nocturnal unilateral convulsions, status epilepticus, focal clonic, generalized tonic-clonic seizures, absence or myoclonic seizures.
2. Developmental regression.

3. Typical EEG, with diffuse, mainly bilateral spikes and waves of 1.5 to 2 Hz, occupying more than 85% of the sleep record and persisting on 3 or more EEG recordings over a period of at least 1 month.

Landau-Kleffner syndrome is a partly reversible epileptic encephalopathy of childhood characterized by acquired verbal auditory agnosia and cognitive and psychological abnormalities. Seizures may occur infrequently and as a rule are easy to control.16- The sleep EEG usually shows high-frequency, sometimes continuous, bilateral spikes and waves, typically over the posterior temporal regions.46-

Atypical benign partial epilepsy was delineated by Aicardi and Chevrie in 1982.7 The designation "atypical benign partial epilepsy" was later replaced with "pseudo-Lennox syndrome" because many elements in its symptomatology resemble Lennox-Gastaut syndrome, with the disorder taking a defective rather than a benign course.8 The initial seizures are of the type found in benign childhood epilepsy with centrotemporal spikes.8 The EEG also displays the characteristic features of benign childhood epilepsy with centrotemporal spikes in every single case, at least transiently.8,9

The authors describe the electroclinical features and the pathogenesis of three children from Saudi Arabia, one with encephalopathy with continuous spikes and waves during sleep, the second with Landau-Kleffner syndrome, and the third with

atypical benign partial epilepsy. We also reviewed the literature regarding these 3 syndromes.

Case 1

W.K. is a 7-year and 7-month-old female child who was healthy up to the age of 1 year and 9

months, at which time she was diagnosed with herpetic encephalitis and admitted to a hospital for

32 days, where she received intravenous acyclovir and antibiotics. In follow-up examination, she was found to have regression of her milestones and severe sensorineural hearing impairment. At the age of 2 years and 10 months she started to

develop complex partial seizures and was treated in another hospital with carbamazepine. A second type of seizure emerged 1 and a half years later in the form of myoclonic jerks, which occurred up to 40 times per day. No tonic seizures were observed. Carbamazepine was substituted with valproate, with subsequent reduction of the number of seizures to 2 to 3 times per day. At the age of 4 years, another type of seizure was noticed by W.K.'s parents in the form of focal seizures that occurred once every 2 to 3 days, usually during sleep and associated sometimes with a scream. At that time levetiracetam was added to valproate and continued for 1 year with little benefit and then was replaced with clonazepam, which caused severe sedation and was discontinued by the mother after 1 month of treatment. As there was no improvement regarding the seizures, the parents stopped all medications for 1 year. At the age of 5 years and 10 months, due to increase in the frequency of her seizures, she was restarted on levetiracetam, again with no obvious improvement regarding her seizures. She experienced seizures of different types almost daily, occurring 10 to 15 times per day. The child was referred to us for the first time when she was 6 years and 2 months old.

Examination showed an apathetic child who could neither hear nor speak. No distinctive features were noted, but frequent brief myoclonic jerks of the upper limbs were observed. She could walk but was not interested in her surroundings. Tone, power, and reflexes were normal, as well as cranial nerves.

A 32-channel video/EEG (V/EEG) recording during natural sleep and wake states was performed and, unexpectedly, generalized, diffuse, high-voltage continuous spikes and waves were seen during sleep only (Figure 1A). Her wake EEG demonstrated multifocal spike-wave complexes at centrotemporal electrodes. Magnetic resonance imaging (MRI) of the brain was done and showed

Table 1 Clinical and EEG characteristic of 3 patients with ECSWS, LKS, and ABPE

	ECSWS	LKS	ABPE
Incidence	0.2-0.5%	Rare	Rare
Age of onset. peak	4-5 years	5-7 years	3 years
Age of onset. range	2 months-12 years	2-8 years	2-6 years
Family history	Very uncommon (10%)	Very uncommon (3-12%)	Uncommon
Seizures	Majority	70-80%	n
Frequency of	>90%/o	Infrequent	Frequent
<b>SCIZURCS</b>			
Type of seizures	GTCS, typical or atypical absences, SPS, NCSE, NM, atonic seizures	GTCS, SPS, atypical absences, atonic seizures, minor motor seizures, NCSE	Atonic seizures, "Rolandic" seizures, GTCS, Absences, NM
Neuropsychological status	Cognitive decline, inattention, agitation, disinhibition, language disturbances, behavioral abnormalities	Verbal auditory agnosia, cognitive decline, behavioral abnormalities	Mental slowing, mild to moderate behavioral abnormalities, language delay (>50%).
Etiology	Unknown. 50% abnormal before onset (pre- or perinatal illness, congenital hemiparesis, ataxia, psychomotor or language deficits)	Unknown. Most are normal before onset of disease.	Unknown. 50% minor to remarkable neurological abnormalities (coordination deficits, mild hemi- or tetraparesis)
<b>Pathophysiology</b>			
EEG	HIBM Awake: focal or multifocal spikes. Sleep: Bilateral (anterior/central). continuous spike-wave discharges. SWI >85%	HIBM Awake: focal or multifocal spikes. Sleep: Bilateral (temporal). continuous spike-wave discharges. SWI <85%	HIBM Awake: unilateral or bilateral CTS Sleep: Bilateral continuous spike-wave discharges or hypersarrhythmic-like
MRI/CT brain	>30% abnormal	Usually normal	Usually normal
Prognosis	Seizure: remit in all patients Cognitive/behavioral abnormalities: majority have partial improvement	Seizure: remit in all patients Cognitive/behavioral abnormalities: 20% improve completely	

left temporoparietal and right temporal cystic encephalomalacia associated with areas of increased hyperintensities on T2 and fluid-attenuated inversion recovery in the periventricular regions, highly suggestive of leukodystrophies. Auditory brainstem evoked potentials showed severe bilateral sensorineural deafness. The child was diagnosed as having encephalopathy with continuous spikes and waves during sleep and started on 80 international units (IU) of adrenocorticotrophic hormone (ACTH) intramuscularly (IM) once per day for 2 months. A repeat V/EEG was performed and showed almost normalization of the record (Figure 1B). Topiramate in a dose of 6 mg/Kg/day was added to the ACTH, and the child became seizure free for 1 year. The child was followed for 1 year and 6 months, and although no formal psychological testing was performed, her personality and reactivity to external stimuli improved significantly and no more seizures were reported.

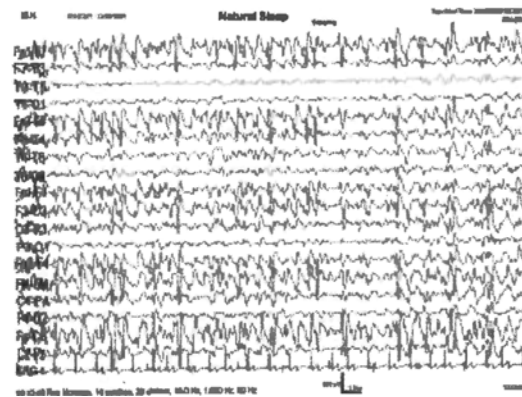
Case2

A.A. was a full-term male infant, a product of a normal pregnancy and delivery. The mother had a history of 2 abortions. His parents are first-degree cousins. There is no family history of a similar condition. Initially, the child was developing well; he smiled socially at 6 weeks, turned over at 5 months, developed polysyllabic speech at 9 months, sat without support at 10 months, and at 3 years he was able to produce 3-sentence speeches. A brief febrile seizure was reported at the age of 16 months. Up to the age of 3 years he was socially interactive, playing with other children and his parents expressed no concern about his hearing. Immediately after he reached his third year, he started to manifest irritability as well as interrupted sleep at night associated with inconsolable crying. The parents sought medical advice many times, but they were reassured there was nothing to be concerned about. At the age of 3 years and 4 months, he was admitted to a hospital due to a febrile illness, from which he recovered completely after a few days. Following this, the parents noticed a gradual regression in his speech over a 1-year period, until by the age of 4 years and 3 months he was unable to speak a word. They noticed a gradual inability of the child

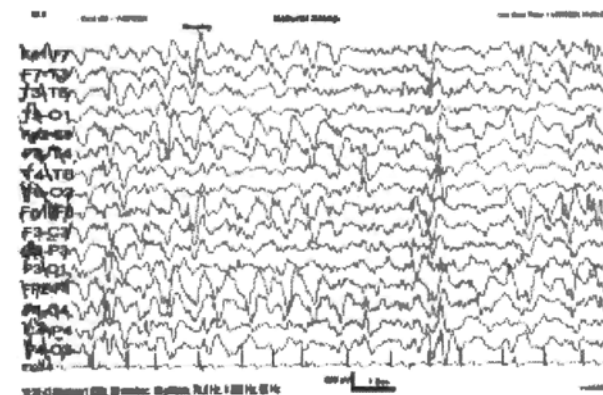
to respond to their calls despite raising their voices. He also became hyperactive and aggressive and lost interest in playing with other children.

A

Figure 1. Case 1 (ECSWS). (A) Generalized,



diffuse, high-voltage continuous spike-wave



complexes during sleep, predominantly at frontocentral region. (B) EEG shows almost "normalization" of sleep record after treating with ACTH.

At that time the child was referred to a psychiatrist and started on methylphenidate and then on risperidone for 1 year, with no clear benefit. The medications were stopped by the parents later on. At the age of 5 years and 4 months, A.A. was referred to a paediatric neurologist, who ordered an MRI brain scan, which was reported as normal. Sleep EEG was attempted 2 times but on both occasions the child did not sleep. The wake EEG was reported as normal. Three months later, at the age of 5 years and

7 months, he started to develop atonic seizures with head drop, once per week, which was considered initially by the family as a normal behavior. At the age of 5 years and 10 months he started to have nocturnal generalized tonic-clonic seizures every 2 to 3 months. No tonic seizures occurred. The patient was seen for the first time in our hospital at the age of 6 years. Neurologically, the patient had severe hyperactivity. He did not respond to verbal commands, but he showed normal power, tone, and reflexes. Height, weight, and head circumference were within the 50th centile for age and sex. No skin stigmata were noticed, and cranial nerves were intact. Extensive laboratory tests were performed including complete blood count and renal and liver function tests; all were normal. Blood tandem mass spectrometry and urine gas chromatography for metabolic causes was reported as unremarkable. Serum and cerebrospinal fluid pyruvate and lactate were within normal limits for age. A natural sleep EEG finally was successfully obtained after partial sleep deprivation. The EEG showed generalized, high-voltage, continuous spikes and waves during sleep. The child was diagnosed as having Landau-Kleffner syndrome and was started by us on 80 IU of ACTH IM daily for 2 months with regular checkup of his blood pressure, blood sugar, and electrolytes. Two months after treatment a repeated video-EEG was done and showed a normal sleep and wake record. Valproate on an increasing dose up to 40 mg/kg/day and topiramate of 6mg/kg/day were added. The child was followed regularly for 3 years. No more seizures were reported. Although no formal psychomotor testing was performed, at the age of 11 years and 2 months he was more interactive, played with his siblings, obeyed simple commands, and was able to speak 3-word sentences.

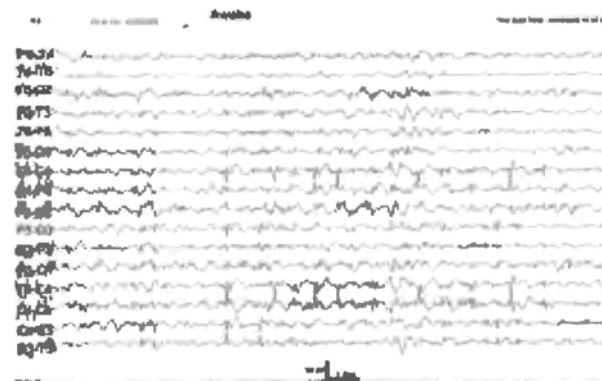
A.

B.

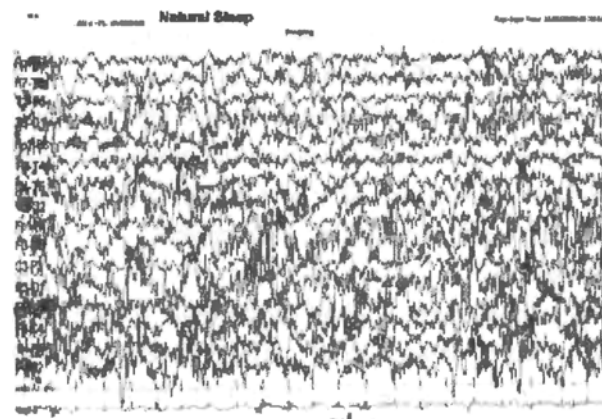
Figure 2. Case 3 (ABPE). (A) Wake interictal EEG showed bilateral centrotemporal "Rolandic" spikes. (B) Sleep interictal EEG showed generalized, high-amplitude multifocal spikes, hypsarrhythmia-like pattern.

Case3

M.S. is a 3-year and 6-month-old boy who was



followed in our paediatric neurology clinic due



to stagnation of his milestones. Pregnancy and delivery were uneventful. Parents are second-degree cousins, and they have an older female child with developmental regression of unknown etiology. There are 3 other, older female children who are well. M.S. smiled at 4 weeks of age, rolled over at 6 months, and sat with support at 6 months. He started to coo, vocalize, and respond to his own name at 6 months, and obtained polysyllabic babbling at 9 months. After that the mother noticed that he did not commence to crawl, and he still could not sit without support at 10 months. At the age of 14 months, the child could not say a word, and continued to be unable to sit or stand without support. At the age of 2 years the parents noticed daily myoclonic seizures, which were initially observed during the night and later on also during the day. Generalized tonic-clonic seizures occurred once when the patient was 3 years old. No tonic seizures were reported.

On examination, he looked to be a cheerful child,

interested in his surroundings, and had no distinctive features. His occipitofrontal head circumference was on the 75th centile, and he had appropriate height and weight. There were no skin stigmata of neurocutaneous disorders. MRI brain scan was normal. Fundoscopy was normal, as well as hearing assessment. His wake interictal EEG showed bilateral centrotemporal spikes as observed in benign epilepsy of childhood with centrotemporal spikes (Figure 2A) and a hypsarrhythmia-like pattern during natural sleep (Figure 2B). The child was started on ACTH IM, in a dose of 80 IU daily, for 1 month in addition to levetiracetam in a dose of 20 mg/kg/day in 2 divided doses. The child was followed for 1 year and 6 months, and although no formal psychological testing was performed, the child observably improved and started to speak a few words. No more seizures were reported after starting of treatment.

### Discussion

Encephalopathy with continuous spikes and waves during sleep is a rare childhood syndrome that is difficult to diagnose and treat. Fifty percent of the children affected are normal before the onset of the disease. There are 3 stages of evolution.<sup>2,10,11</sup> The first stage is before the discovery of the continuous spikes and waves during sleep and is characterized by nocturnal complex or simple partial seizures and generalized tonic-clonic seizures. The EEG at this stage shows multifocal spikes and generalized spike-wave complexes. The second stage starts 1 to 2 years after the first seizure. Seizures become more frequent, and new types of seizures emerge. These include myoclonic absences, negative myoclonus, nonconvulsive status epilepticus, and drop attacks. The insidious decline of the neuropsychological condition of the child is the most dramatic and disturbing aspect. Hyperkinesia, agitation, aggressiveness, and decreased attention span predominate when continuous spikes and waves during sleep are frontal. Temporal lobe continuous

spikes and waves during sleep produce linguistic and verbal disturbances. The third stage starts 2 to 7 years from onset. There is gradual incomplete remission of the neuropsychological state, and seizures stop completely.

In case 1, the child went through the 3 stages. Although more than a third of patients with encephalopathy with continuous spikes and waves during sleep have an abnormal pathology such as brain atrophy, focal porencephaly, and developmental cortical malformations,<sup>2,10,11</sup> to our knowledge documented encephalopathy with continuous spikes and waves during sleep following herpetic encephalitis has not been reported. One case of nonconvulsive status epilepticus caused by herpes encephalitis was reported<sup>12</sup> but it was not associated with encephalopathy with continuous spikes and waves during sleep. The symptomatology of patients with encephalopathy with continuous spikes and waves during sleep overlaps with other patients with Landau-Kleffner syndrome and atypical benign partial epilepsy, as demonstrated in our 3 cases (Table 1). This was thoroughly investigated by Hahn et al.<sup>13</sup>

The 3 syndromes share tonic-clonic generalized seizures and myoclonic jerks, and our 3 patients did not develop tonic seizures. Tonic seizures are probably incompatible with diagnosis of encephalopathy with continuous spikes and waves during sleep and Landau-Kleffner syndrome,<sup>2,10,11</sup> and in a series of 43 patients with atypical benign partial epilepsy who were analyzed by Hahn et al.<sup>13</sup> no tonic seizures were observed.

Landau-Kleffner syndrome is a partly reversible, epileptic encephalopathy of childhood; the principal signs are acquired verbal auditory agnosia and other linguistic deficits, cognitive and neuropsychological behavioral abnormalities, and epilepsy in a previously normal child who has already developed age-appropriate speech.<sup>2,10,11</sup> Seizures are infrequent

(occurring in 70% to 80% of cases) and are not a prerequisite for the diagnosis of Landau-Kleffner syndrome (Table 1).<sup>2,10,11</sup>

In case 2, with Landau-Kleffner syndrome, the child was developing well before his illness and obtained his age-appropriate speech milestones. His serial MRI brain studies did not detect any abnormalities. As in case 2, in Landau-Kleffner syndrome there are usually no detectable underlying structural abnormalities, and the MRI of the brain is normal.<sup>2,10,11</sup>

The EEGs of cases 1 and 2 showed generalized, high-voltage continuous spikes and waves during sleep. Continuous spikes and waves during sleep occur at one stage during sleep in all patients with Landau-Kleffner syndrome, although it is not a prerequisite for diagnosis. The sharp-slow complexes are usually in the posterior temporal regions, whereas the continuous spikes and waves during sleep in encephalopathy with continuous spikes and waves during sleep are higher in amplitude at the anterior and central regions.<sup>2,3,6,10</sup> This was documented in cases 1 and 2. The spike-wave index (SWI), which is the sum of all spikes in minutes multiplied by 100 and divided by the total duration of NREM sleep in minutes, is usually more than 85% in patients with encephalopathy with continuous spikes and waves during sleep, while most patients with Landau-Kleffner syndrome demonstrate a lower SWI (Table 1).<sup>2,3,6,8,11</sup> Case 1, with encephalopathy with continuous spikes and waves during sleep, showed SWI of more than 90%, and case 2, with Landau-Kleffner syndrome, was about 60%.

Atypical benign partial epilepsy/pseudo-Lennox syndrome shows a broad electroclinical spectrum and a variable course.<sup>7,10,13,14</sup> This ranges from patients with a short period of seizure activity and normal neuropsychological development to patients with long-lasting epilepsy, a massive extent of epileptic discharges, and persistent

neuropsychological impairment.<sup>7,10,13,14</sup> The seizures, as demonstrated in case 3, include simple focal seizures, generalized minor seizures, and generalized tonic-clonic seizures.<sup>8,11,13,14</sup> According to Hahn et al., myoclonic seizures are rarely seen in patients with atypical benign partial epilepsy.<sup>13</sup> In case 3, with atypical benign partial epilepsy, the predominant seizures were of the myoclonic type.

The wake EEG in patients with atypical benign partial epilepsy shows centrotemporal spikes, often bilateral, and similar to these seen in patients with benign childhood epilepsy with centrotemporal spikes,<sup>8,9</sup> and this was also observed in case 3. Although the sleep EEG in patients with atypical benign partial epilepsy is similar to that of patients with encephalopathy with continuous spikes and waves during sleep and Landau-Kleffner syndrome, this was not observed in our patient (case 3). However, during sleep a hypsarrhythmia-like pattern was seen (Figure 4). This unique pattern has been mentioned by other authors.<sup>8,9,13</sup>

A common pathophysiological mechanism that may explain the similarities and overlap between encephalopathy with continuous spikes and waves during sleep, Landau-Kleffner syndrome, and atypical benign partial epilepsy (Table 1) is the concept of hereditary impairment of brain maturation.<sup>9,13,15</sup> The genetic predisposition responsible for hereditary impairment of brain maturation plays a dominant part in the pathogenesis of atypical benign partial epilepsy and Landau-Kleffner syndrome.<sup>2,6,8,9</sup>

There is a suggestion from family studies that benign sharp waves are probably transmitted as an autosomal dominant trait.<sup>16</sup> The spectrum of conditions that can be explained by the concept of hereditary impairment of brain maturation ranges from neonatal seizures, febrile seizures, and benign childhood epilepsy with centrotemporal spikes, to severe epilepsies such as atypical benign partial

epilepsy/pseudo-Lennox syndrome and epileptic encephalopathies such as encephalopathy with continuous spikes and waves during sleep and Landau-Kleffner syndrome.<sup>2,6,8,9</sup> The neuropsychological impairment in encephalopathy with continuous spikes and waves during sleep and Landau-Kleffner syndrome has been attributed by other authors to the effect of continuous spikes and waves during sleep.<sup>1,2,6,11</sup> In our opinion this concept may be applied also to atypical benign partial epilepsy/pseudo-Lennox syndrome.

The pattern of neuropsychological derangement depends on the location of the continuous spikes and waves during sleep. Linguistic impairment, as in Landau-Kleffner syndrome, relates to epileptogenic foci over temporal lobe regions, whereas mental deterioration and autistic behavior relates to frontal-lobe epileptogenic foci, as in patients with encephalopathy with continuous spikes and waves during sleep.<sup>1,2,6,10,12</sup>

The management of encephalopathy with continuous spikes and waves during sleep, Landau-Kleffner syndrome, and to a lesser degree atypical benign partial epilepsy/pseudo-Lennox syndrome is empirical and of transient efficacy. Seizures are infrequent, age limited, and often easily to control with antiepileptic drugs.<sup>10,11,17</sup> It is usually agreed that treatment with antiepileptic drugs should start with valproate, clonazepam or clobazam, and sulthiame alone or in combination.<sup>10,11,17</sup> The second line of medical treatment is to start with ACTH or prednisolone, particularly in new and younger children, who may respond better and need shorter steroid treatment and probably should not be delayed more than 1 to 2 months after the initial diagnosis.<sup>11,17</sup> Our cases (1 and 2) responded dramatically regarding the seizures and behavioral and linguistics abnormalities after administration of ACTH. Levetiracetam is a highly effective, broad-

spectrum, new class of antiepileptic drug that has been used successfully in partial or generalized epilepsies and idiopathic or symptomatic epileptic syndromes of all ages.<sup>11,18</sup> Case 1 did not respond to levetiracetam, but it proved effective in case 3. Controlled and long-term studies have demonstrated the efficacy of topiramate in a wide range of seizures and epilepsies.<sup>19</sup> Case 2 responded to topiramate in addition to ACTH.

In conclusion, encephalopathy with continuous spikes and waves during sleep, Landau-Kleffner syndrome, and atypical benign partial epilepsy/pseudo-Lennox syndrome are 3 epileptic encephalopathies with a spectrum of severity ranging from severe cognitive, neuropsychological, and linguistic abnormalities as in patients with encephalopathy with continuous spikes and waves during sleep or Landau-Kleffner syndrome, to less severe and sometimes completely reversible disorders, as in patients with atypical benign partial epilepsy. Several antiepileptic drugs are reported to be beneficial in treating these syndromes. ACTH appears to have favorable and long-lasting effects.<sup>6,20,21</sup> Infants and children with developmental and speech regression associated with abnormal behavior warrant thorough investigation, including EEG for selected cases.

**Abbreviations:** ABPE, atypical benign partial epilepsy; CTS, centrotemporal spikes, ECSWS, encephalopathy with continuous spikes and waves during sleep; GTCS, generalized tonic-clonic seizures; HIBM, hereditary impairment of brain maturation; LKS, Landau-Kleffner syndrome; NCSE, nonconvulsive status epilepticus; NM, negative myoclonus; SPS, simple partial seizures; SWI; spike-wave index.

#### References

1. Beaumanoir A, Bureau M, Deonna T, Mira L, Tassinari CA, et al., eds. *Continuous Spike and Wave during*

- Sleep. Electrical Status Epilepticus during Sleep.* London: John Libbey; 1995.
2. Tassinari C.A, Rubboli G, Volpi L, Billard, C, Bureau, M. *Electrical status epilepticus during slow sleep (electrical status epilepticus during sleep or continuous spikes and waves during sleep) including acquired epileptic aphasia (Landau-Kleffner syndrome).* In Roger J, Bureau M, Dravet C, et al., eds. *Epileptic syndromes in infancy, childhood and adolescence.* 4th ed. London: John Libbey; 2005:295314-.
  3. Landau WM, Kleffner FR. *Syndrome of acquired aphasia with convulsive disorder in children.* *Neurology.* 1957;7:523530-.
  4. Me Vicar KA, Shinnar S. *Landau-Kleffner syndrome, electrical status epilepticus in slow wave sleep and language regression in children.* *Ment Retard Dev Disabil Res Rev.* 2004;10: 144149-.
  5. Camfield P, Camfield C. *Epileptic syndromes in childhood: clinical features, outcomes, and treatment.* *Epilepsia.* 2002;43:2732-.
  6. Hirsch E, Valenti MP, Rudolf G, Seegmuller C, Martin AS, Maquet P, Wioland N, Metz-Lutz MN et al. *Landau-Kleffner syndrome is not an eponymic of badge ignorance.* *Epilepsy Res.* 2006;70S:S239247-.
  7. Aicardi J, Chevrie JJ. *Atypical benign partial epilepsy of childhood.* *Dev Med Child Neural.* 1982;24:281292-.
  8. Dose H, Ernst JP, Castiglione E, Diebold U. *Pseudo-Lennox Syndrom und verwandte Krankheitsbilder- frontale Epilepsien?* In *Aktuelle Neuropadiatrie* 1991. Berlin: Kohler B. Springer; 1992.
  9. Dose H. *EEG in Childhood Epilepsy: Initial Presentation and Long-term Follow-up.* John Libbey Eurotext; 2003.
  10. Panayiotopoulos CP. *A Clinical Guide to Epileptic Syndromes and Their Treatment.* London: Springer; 2007.
  11. Nieuwenhuis L, Nicolai J. *The pathophysiological mechanisms of cognitive and behavioral disturbances in children with Landau-Kleffner syndrome or epilepsy with continuous spike-and-waves during slow-wave sleep.* *Seizure.* 2006;15:249258-.
  12. Gunduz A, Beskardes AF, Kutlu A, Ozkara C, Karaagac N, Yeni S N. *Herpes encephalitis as a cause of nonconvulsive status epilepticus.* *Epileptic Disord.* 2006;8:5760-.
  13. Hahn A, Pistahl J, Neubauer BA, Stephani U. *Atypical "benign" partial epilepsy or pseudo-Lennox syndrome. Part I: symptomatology and long-term prognosis.* *Neuropaediatrics.* 2001;32:18-.
  14. Hahn A. *Atypical benign partial epilepsy/pseudo-Lennox syndrome.* *Epileptic Disord.* 2000;2:4549-.
  15. Dose H, Neubauer BA, Petersen B. *The concept of hereditary impairment of brain maturation.* *Epileptic Disord.* 2000;2:S45-S49.
  16. Bray PF, Wisner WC. *Evidence for a genetic etiology of temporal-central abnormalities in focal epilepsy.* *New Eng J Med.* 1964;271:926933-.
  17. Mikati MA, Shamseldine AN. *Management of Landau-Kleffner syndrome.* *Pediatr Drugs.* 2005;7:377389-.
  18. Glauser TA, Pellock JM, Bebin EM, Ritter FJ, Jensen CM, et al. *Efficacy and safety of levetiracetam in children with partial seizures: an open-label trial.* *Epilepsia.* 2002;43:518524-.
  19. Mikaeloff Y, de Saint-Martin A, Mancini J, et al. *Topiramate: efficacy and tolerability in children according to epilepsy syndromes.* *Epilepsy Res.* 2003;53:225232-.
  20. Smith M. *Landau-Kleffner syndrome and continuous spikes and waves during slow sleep.* In Engel JJ, Pedley TA, eds. *Epilepsy: A Comprehensive Textbook.* Philadelphia, PA: Lippincott-Raven; 1998:2367-2377.
  21. Inutsuka M, Kobayashi K, Oka M, Hattori J, Ohtsuka Y. *Treatment of epilepsy with electrical status epilepticus during slow sleep and its related disorders.* *Brain Dev.* 2006;28:281286-.