

A CASE OF TRUE HERMAPHRODITISM PRESENTING AT THE AGE OF THIRTEEN

Dr. Amani Gindeel, MD. Khartoum

Intersex conditions are among the most fascinating conditions encountered by the clinician. They are not as rare as once perceived and pose numerous difficulties on the clinicians, families, and patients. This is further complicated by social, cultural and religious considerations.

In true gonadal intersex, formerly known as true hermaphroditism, both ovarian and testicular tissues are present, either in the same (ovotestis) or in opposite gonads (1). Ovotestis is the most encountered (2). Affected patients have ambiguous genitals (1).

Fewer than 10% of patients with true intersex have a 46,XY karyotype (1), the majority being 46,XX (2).

A thirteen year old male who resides with his grandmother away from his consanguineous parents and four other siblings, presented to the casualty of Bahri Teaching Hospital on September 2004. Accompanied by his uncle, complaining of recurrent Left lower abdominal pain for two days. This pain was constant, not alleviated with analgesics and not associated with gastrointestinal or renal symptoms, but urination was performed only assuming a sitting position. Examination revealed an ill looking, well-grown patient in severe pain, bilateral gynecomastia,

- Abdominal examination showed a left irreducible inguinal mass of 4x3 cm, left sided undescended testis and ambiguous genitalia with severe hypospadias (perineal urethral opening) and tight chordee. The stretched penile length was between the tenth and fiftieth

centiles . Penile Width was 2.5 cm, and the testicular volume approximately 4 ml.

Tanner sexual maturity rating for pubic hair was SMR3 and for the genitalia was SMR2. Secondary sexual characteristics in form of facial acne, axillary perspiration, axillary hair, coupled with a given history of early morning erection were all suggestive of appropriate male pubertal development. The patient was admitted for relief of pain , and surgical consultation , and was discharged to be seen as an outpatient for further evaluation proper expert consultation, and management.

Follow up over the following six months revealed similar abdominal pains recurring every 3-5 weeks , each lasting 3-7 days , associated with the appearance of an inguinal mass.

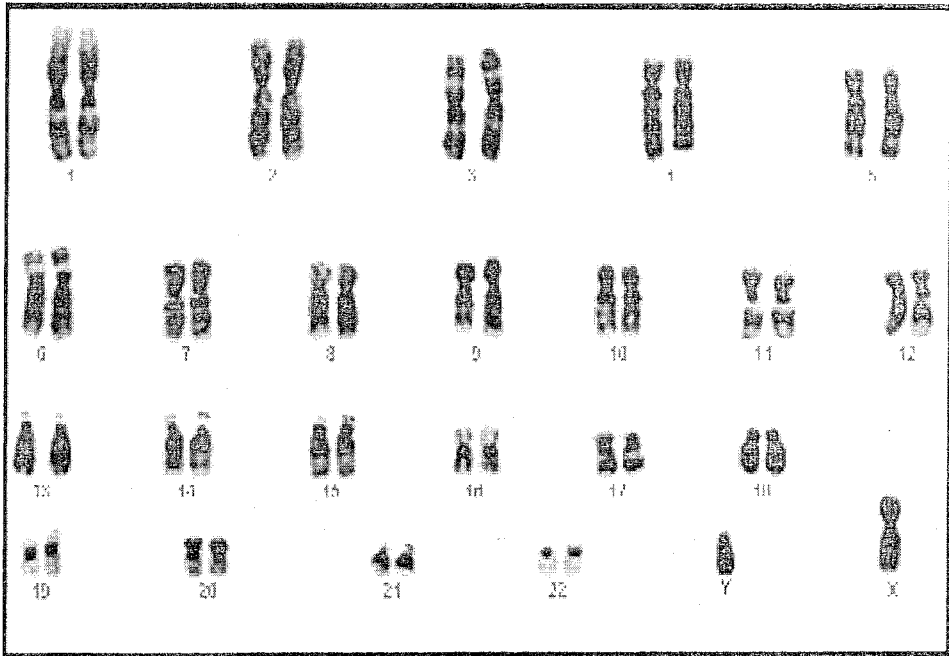
Investigations performed revealed normal complete blood count , Urine general and culture.

Abdominal and pelvic ultrasounds reported a 3.5x2.1cm oval shaped structure in the Lt inguinal region, that suggest an

- Undescended testicle, below it there was a smaller rounded structure of low echogenicity, nature of which uncertain. Normal sized right testicle. Normal urinary
- bladder with a small uterus like structure posteriorly, No pelvic masses or ovaries seen.

A micturating cystourethrogram was then performed. After several times of micturition trials the flow of urine was through an opening below the testis.

Karyotyping was done and showed a normal male pattern of 46 XY. Then hormonal assays were undertaken and results showed normal levels of prolactin, follicle stimulating hormone and testosterone, with slightly high luteinizing hormone reaching 15.8 ml U/L (normal up to 9).



□ Management of the patient required a rapid diagnosis and a guarded approach considering the late age of presentation and the complicated circumstances of the absence of parents who live in a distant area, and needed to be involved. An eminent Paediatric endocrinologist was consulted, paediatric surgeon, a urologist and Genetist were involved. A preliminary diagnosis of Intersex was made, being either testicular dysgenesis or true gonadal intersex (true Hermaphrodite)

□ As well, a fatwa by Ulama Council concerning gender assignment according to the Islamic laws was obtained.

□ The patient was informed thereafter in the presence of his family and doctors of the diagnosis and treatment options, and he and his family expressed their wish for his final assignment as a male. A laparotomy was performed, where removal of the inguinal mass was undertaken and the right testis was examined. Release of the chordee resulted in correction of the penile curvature, and a future plan was made for correcting the hypospadias and mastectomy was made. The histopathology result of the specimen showed the following:

□ Macro: The specimen consisted of the left ovary, tube and uterus. The body of the uterus measured 4x4x2 cm in its greatest dimensions. The cervix was small. The tube is normal. The ovary measured 5 cm in length.

Micro: The endometrium shows glands lined by tall columnar epithelium with no secretory activity. The glands are lying back to back with little intervening stroma. The rest of the stroma is compact. The cervix contains two foci of endometrial glands and stroma. The myometrium and tube are normal.

The ovary contains corpus luteum and several Graffian follicles.

Diagnosis: Functioning right ovary, complex endometrial hyperplasia.

□ Endometriosis of the cervix and normal myometrium and tube.

□ In view of the investigations mentioned a diagnosis of TRUE GONADAL INTERSEX was made. A plan for complete surgical correction was set, and the patient and family were actively involved and satisfied.

- With proper follow up the need may arise for use of hormonal therapy.

Islamic guidelines in sex reassignment

The Islamic religious leaders have issued more than one fatwa indicating that definitely males or females should not be assigned the opposite sex.(3, 4)

The current Islamic recommendations put forward by the Senior Ulama Council in Saudi Arabia, statement No. 176. dated 17.3.1413H^{ls} gives very useful general statements which fulfill the scientific facts and indications. These recommendations are translated as follows:

- 1) A sex-change operation, i.e.. Converting a completely developed gender to the opposite (sex. is totally prohibited. It is considered criminal. This is clearly supported by the Holy Koran and the Prophet's sayings'.
- 2) Those who have both male and female organs need to be investigated and if the evidence is more male, it is then permissible to treat him medically (bv hormones or surgery), to eliminate his ambiguity, and raise him as a male; if the evidence is more female, it is permissible to treat her medically (bv hormones or surgery) to eliminate her ambiguity, and raise her as a female.
- 3) Physicians must explain the results of medical investigations to the child's guardian (be it a male or a female) so they may be well informed.

REFERENCES:

1. Robert Rapaport. Disorders of the gonads. In: Richard E.Behrman, Robert M.Kliegman, Hal B. Jenson. Nelson Textbook of pediatrics, ed Philadelphia, Saunders: 2004:p1945-46.
2. Aleck KA, Argueso L, Stone J, et al: True hermaphroditism with partial duplication of chromosome 22 and without SRY . Am J Med Genet 85:2, 1999.
3. Abdullah MA. Ambiguous genitalia: medical, socio-cultural and religious factors affecting management in Saudi Arabia. Abdullah MA et al. Annals of tropical paediatrics 1991;11,343-48.
4. Al Herbish et al. Sex reassignment: a challenging problem. Current medical and Islamic Guidelines. Annals of Saudi Medicine 1996; 16,!:12-15.