

Zellweger syndrome: A cause of neonatal hypotonia and seizures

Abdelmoneim E. M. Kheir

Department of Pediatrics, Dallah Hospital, Riyadh, Saudi Arabia

ABSTRACT

Zellweger syndrome, a paradigm of human peroxisomal disorders is characterized by dysmorphic features, hypotonia, severe neuro-developmental delay, hepatomegaly, renal cysts, sensorineural deafness and retinal dysfunction. This is a case report of a baby boy born with facial dysmorphism, profound hypotonia, seizures, and hepatomegaly. The diagnosis was not evident initially but only later when he presented with obstructive jaundiced and renal cysts. He died at the age of seven months. Biochemical studies revealed elevation of very long chain fatty acids and phytanic acid consistent with a peroxisomal disorder. The recognition of this syndrome is important since it is a fatal hereditary disease. Zellweger syndrome should be included in the differential diagnosis of infantile hypotonia and dysmorphism.

Key words: Zellweger syndrome; Peroxisomal disorders; Child

INTRODUCTION

The Peroxisomal disorders constitute clinically and biochemically heterogeneous group of disease states sharing an impairment of one or more peroxisomal functions [1]. Up to now, at least 21 disorders have been found which are linked to peroxisomal dysfunction. Most of these show severe central nervous system (CNS) involvement [2].

Peroxisomes are sub cellular organelles, surrounded by a single membrane, 80 peroxisomal enzymes have been identified. Peroxisomes are present in all human cells except in mature erythrocytes and are particularly abundant in liver and kidney. The most important peroxisomal functions are lipid and amino acid metabolism, bile acid biosynthesis, B- oxidation of fatty acids, phytanic acid α oxidation, plasmalogen biosynthesis – involved in platelet activation and scavenging of free radicals [3].

The first indication that peroxisomes may be involved in human disease came in 1973 when Goldfischer et al [4] noted their apparent absence in the liver and kidney of a child with a clinical diagnosis of Zellweger syndrome. Zellweger (or cerebrohepato renal) syndrome was originally described as a lethal multiple

Correspondence to:

Dr. Abdelmoneim E. M. Kheir,
Department of Paediatrics,
Faculty of Medicine, P. O. Box 102,
University of Khartoum, Sudan
Email: moneimkheir62@hotmail.com

How to cite this article:

Kheir AEM. Zellweger Syndrome: A cause of neonatal hypotonia and seizures. Sudan J Paediatr 2011;11(2):54-58.

malformation syndrome of infancy [5].

The craniofacial features of Zellweger syndrome are striking. These are characterized by paucity of facial movement with a large anterior fontanelle, prominent forehead, hypoplastic supraorbital ridges and broad nasal root [6]. Other features include severe neurological dysfunction, developmental delay with hypotonia, sensorineural hearing loss and ocular abnormalities namely cataract, and optic nerve hypoplasia. Hepatomegaly is seen in 80% of cases of Zellweger syndrome with raised levels of liver enzymes and bilirubin; renal cortical cysts are seen in 70% of cases [7].

The pattern of inheritance is autosomal recessive, and in three Zellweger patients mutations have been shown to exist in two peroxisomal integral membrane proteins [8].

The main stay of biochemical diagnosis of Zellweger syndrome is the measurement of very long chain fatty acids (VLCFA) which have a chain length of 22 carbon atoms or greater [9]. Other clinically useful assays exist for phytanic acid and pipercolic acid. Histological diagnosis is also possible through liver biopsy by using the diaminobenzidine staining procedure to study the abundance, size and structure of liver peroxisomes [10].

Prenatal diagnosis is also possible by direct analysis of levels of VLCFA and bile acid intermediates in the amniotic fluid. Another approach is the cytochemical staining of peroxisomes in chorionic villous sample. Detailed DNA studies, including immunofluorescence and complementation assays, are now available for confirmation and characterization of the pathological mutation [11-13]. Recent studies in the Middle East gave insight to the molecular phenotype of peroxisomal disorders in the Arab population [11-13]. Unfortunately there is no effective treatment for Zellweger syndrome and patients usually die in the first year of life [14].

CASE REPORT

A male baby (Saudi) was delivered by emergency caesarian section at term due to fetal distress and breech presentation. His Apgar scores were 1 in the 1st minute and 6 in the 5th minute. His anthropometric measurements were as follows: birth weight 2.47 kg; head circumference 33cm; and length 47cm.

The baby needed active resuscitation at birth and was admitted to the neonatal intensive care unit. Further clinical examination revealed dysmorphic features and hypotonia with a wide anterior fontanelle, long philtrum, high arched palate and a broad nasal bridge.

This was the first baby for a young couple who are first degree relatives. There was no antenatal care. The initial arterial blood gases showed severe metabolic acidosis. Subsequently he developed convulsions and was started on intravenous phenobarbitone. Blood sugar and biochemistry were normal. Brain ultrasound was normal. All cultures were negative and weaned off O₂. The baby remained hypotonic with no suck reflex and was commenced on nasogastric feeding.

The following investigations were also done and were normal: complete blood count (CBC), urea and electrolytes (U/E), calcium, magnesium, total serum bilirubin (TSB), creatine kinase, lactate and ammonia. TORCH screening was also negative and chromosomal analysis showed normal female karyotype. Investigations that were found to be abnormal include elevated liver enzymes (raised AST 304 IU/L, raised ALT 121 IU/L). Echocardiography revealed a small atrial septal defect (ASD II: secundum-type).

The baby was discharged home on nasogastric feeding, but was readmitted one week later with obstructive jaundice (TSB 125 mg/dl, direct 92.5 mg/dl). Abdominal ultrasound showed multiple

renal cysts. HIDA scan and spinal X-ray were normal.

A clinical diagnosis of Zellweger syndrome was made and VLCFA were explored (Table 1). An EEG was grossly abnormal and showed left focal epileptogenic activity consistent with partial seizures (Figure 1). MRI brain scan showed delayed myelination of the white matter (Figure 2) and no evidence of ischemic injury. DNA study and skin biopsy for peroxisomal function, immunofluorescence and complementation studies were not done as the parents declined further investigations. The baby had multiple admissions with bronchopneumonia and was O₂ dependent at home. The baby later died peacefully at home at the age of 7 months.

Table 1 Results of long chain fatty acid and phytanic acid*

Fatty acid C₂₂	27.1 µmol/L	(21.1 – 102.8)
Fatty acid C₂₄	53.9 µmol/L	(22.2 – 86-5)
Fatty acid C₂₆	↑9.6 µmol/L	(0.05 – 1.9-7)
C /C ratio_{24 22}	↑ 1.99	(0.0 – 1.15)
C /C ratio_{26 22}	↑0.354	(0.0 – 0.028)
Phytanic acid	↑ 39.89 µmol/L	(0.0 – 10)
Pristanate	↑ 11-15 µmol/L	(0.0 – 1)

* Reference values are in brackets

DISCUSSION

Zellweger's syndrome is a rare hereditary disorder affecting infants and usually results in death. It was named after Hans Zellweger,

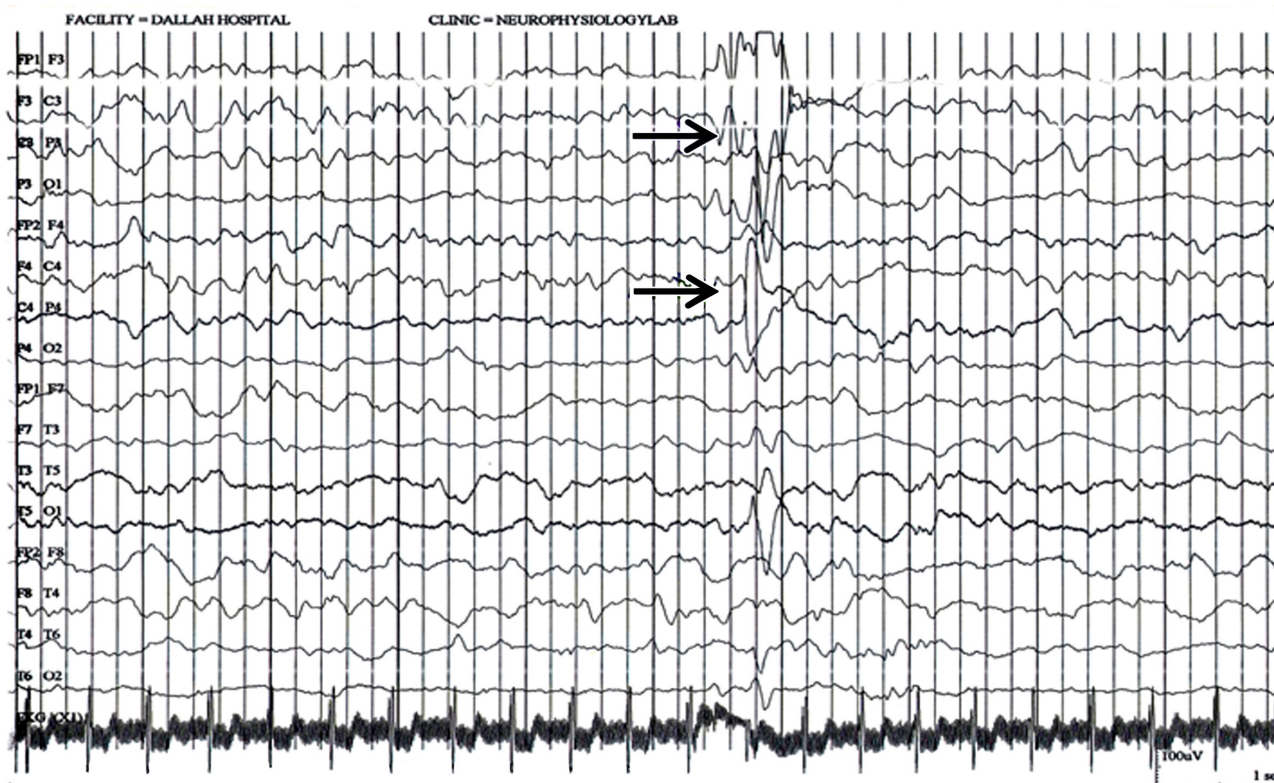
a former professor of paediatrics and genetics at the University of Iowa who researched this disorder. Patients with this syndrome usually have typical facial dysmorphism which may become less characteristic if the patient survives beyond the first year of life. Zellweger syndrome should be considered in any infant who presents with hypotonia and facial dysmorphism [1-8]. In our case, the diagnosis was not evident at birth despite the patient's hypotonia, as the facial dysmorphism was rather nonspecific and the diagnosis was only possible later on when he presented with prolonged conjugated hyperbilirubinemia and routine abdominal ultrasound showed renal cysts which are present in 70% of cases of Zellweger syndrome.

The diagnosis is usually confirmed by finding raised and phytanic acid, in addition to histological detection by either liver biopsy or skin fibroblast culture, both were strongly refused by the parents of our case [1-4].

Currently there is no cure for Zellweger syndrome or a standard course of treatment. Infections should be guarded against to prevent complications such as pneumonia and respiratory distress. Other causes of death include gastrointestinal bleeding and liver failure. Treatment is mainly symptomatic and supportive as patients do not survive beyond one year of age [14].

In conclusion, Zellweger syndrome is one of many dysmorphic syndromes subsequently shown to result from an inborn error of metabolism. Team work between the pediatrician, pediatric neurologist, clinical biochemist and geneticist is the key factor for further delineation; and the recognition of this syndrome is important since it is a fatal inherited disease. Zellweger syndrome should be included in the differential diagnosis of infantile hypotonia and dysmorphism.

Figure 1: An electroencephalogram was grossly abnormal and showed left focal epileptogenic activity



(arrows) consistent with partial seizures.

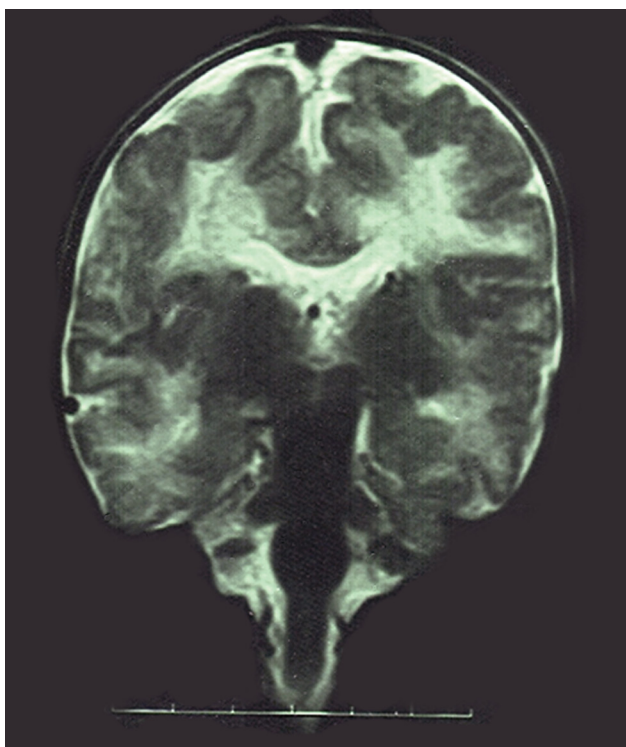


Figure 2: Coronal cut of brain MRI showing delayed myelination of the white matter.

ACKNOWLEDGEMENT

I would like to thank the family of the baby mentioned in this report for permitting the use of the case details. Thanks are also extended to the biochemistry department at Dallah Hospital in Riyadh. I am indebted to Dr. Tarig Dirar, Research Assistant at the Sudan Medical and Scientific Research Institute, for his guidance and assistance during writing up of this case report.

REFERENCES

1. Fournier B, Smeitink JAM, Dorland L, Berger R, Saudubray JM, Poll. Peroxisomal disorders : a review. *J Inherited Metab Dis.* 1994. 17: 470-386.
2. Wander RJA, Heymans HAS, Schutgens RBH, Barth PG, Vander Bosch H, Tager JM. Peroxisomal disorders in neurology. *J Neurol Sci.* 1988. 88: 1-39.
3. Vander Bosch H, Schutgens RBH, Wander RJA, TagerJG. Biochemistry of peroxisomes. *Annu Rev Biochem.* 1992. 61: 157-197.
4. Goldfischer S, Moore CL, Johnson AB, Spiro AJ, Valsamis MP, Wisniewski HK, et al. Peroxisomal and mitochondrial defects in cerebrohepatorenal syndrome. *Science.* 1973;182:62-4.
5. Bowen P, Lee CSN, Zellweger H, Lindenberg R. A familial syndrome of multiple congenital defects. *Bull Johns Hopkins Hosp.* 1964; 114: 402-14.
6. Fitzpatrick DR , Zellweger's syndrome and associated phenotype, *J M genet* 1996;33(10):863-868.
7. Gilchrist KW, Gilbert EF, Shahidi NT, opitzJM. the evaluation of infants with Zellweger's syndrome, *Clin genet* 1975; 7:413-16.
8. Gartner J, Moser H, Valle D. Mutations in the 70K Peroxisomal membrane protein gene in Zellweger's syndrome, *Nat Genet.* 1992 ; (1) :16-23.
9. Wanders RJA, Schrakamp G, van den Bosch H, Tager JM, Moser HW, Moser, AE, et al. Pre and postnatal diagnosis of Zellweger's syndrome. *J Inherit Metab Dis.* 1986; 9 (2)317-320.
10. Roels F, Espeel M, de Craemer D. Liver pathology and immunocytochemistry in congenital peroxisomal diseases: a review. *J Inherited Metab Dis.* 1991; 14 :853-875.
11. Shaheen R, Al-Dirbashi ZN, Al-Hassnan OY, Al-Owain M, Makhseed N, Basheeri F, et al. Clinical, biochemical and molecular characterization of peroxisomal diseases in Arabs. *Clin Genet* 2010;1-11.
12. Al-Dirbashi OY, Shaheen R, Al-Sayed M, Al-Dosari M, Makhseed N, Abu Safieh L, et al. Zellweger syndrome caused by PEX13 deficiency: report of two novel mutations. *Am J Med Genet A.* 2009 ;149A(6):1219-23.
13. Mohamed S, Elmeleagy E, Nasr A, Ebberink M, Wanders R, Waterham H. A Mutation in PEX19 Causes a Severe Clinical Phenotype in a Patient With Peroxisomal Biogenesis Disorder. *Am J Med Genet Part A* 2010; 152A:2318–2321.
14. Steinberg S, Dodt G, Raymond G, Braverman N, Moser A, Moser H. Peroxisomes biogenesis disorders. *Biochimica Biophysica.* 2006; 1733-1763.