

Case report

Idiopathic neonatal hepatitis or extrahepatic biliary atresia? The role of liver biopsy

Abdelmoneim EM Kheir (1), Wisal MA Ahmed (2), Israa Gaber (2), Sara MA Gafer (2), Badreldin M Yousif (3)

- (1) Department of Paediatrics and Child Health, Faculty of Medicine, University of Khartoum and Soba University Hospital, Sudan
 - (2) Department of Paediatrics. Soba University Hospital, Khartoum, Sudan
 - (3) Department of Pathology, Faculty of Medicine, University of Bahri, Sudan
-

ABSTRACT

Cholestasis in early infancy represents a diagnostic dilemma and most of these infants suffer either from extrahepatic biliary atresia or idiopathic neonatal hepatitis. Differentiation between the two conditions may be extremely difficult both clinically and biochemically, and a diagnostic liver biopsy is usually required. We report on a Sudanese infant who presented at the age of 4 weeks with prolonged cholestatic jaundice, abdominal ultrasound was inconclusive, HIDA scan was suggestive of extrahepatic biliary atresia and the diagnosis of idiopathic neonatal

hepatitis was only reached by liver biopsy. The infant made full recovery on supportive treatment during a one year follow up period.

Keywords:

Idiopathic neonatal hepatitis; Conjugated hyperbilirubinemia; Giant-cell hepatitis; Liver biopsy.

Correspondence to:

Dr. Abdelmoneim E M Kheir,
Associate Professor,
Department of Paediatrics and Child Health,
Faculty of Medicine, University of Khartoum and
Soba University Hospital,
P.O. Box 102, Khartoum, Sudan.
Mobile: +249 9 12313110
Fax: +249 183776295
E-mail: moneimkheir62@hotmail.com

How to cite this article:

Kheir AEM, Ahmed WMA, Gaber I, Gafer SMA, Yousif BM. Idiopathic neonatal hepatitis or extrahepatic biliary atresia? The role of liver biopsy. Sudan J Paediatr 2016;16(1):58 - 62.

INTRODUCTION

Cholestasis in early infancy is usually difficult to diagnose initially. Most of these infants suffer either from extrahepatic biliary atresia (EHBA) or idiopathic neonatal hepatitis (INH). In about 25% to 50% of infants presenting with conjugated hyperbilirubinemia within the first three months of life, no cause is found [1, 2]. Neonatal hepatitis may be caused by metabolic diseases, viruses or genetic disorders. In INH, however, the cause of inflammation remains unknown. The affected neonates have jaundice, dark urine, light or pale stools, hepatomegaly and varying degrees of coagulopathy may also be seen [3].

Since INH is a disease of the newborn and the natural history is of gradual resolution in most cases, differentiation from EHBA might be extremely difficult and liver biopsy is usually required for differentiation [4]. Sporadic and familial cases of INH have been described [5].

We report on a Sudanese infant who presented at the age of 4 weeks with prolonged cholestatic jaundice, abdominal ultrasound was inconclusive, hepatobiliary iminodiacetic acid (HIDA) scan was suggestive of EHBA and the diagnosis of INH was only reached by liver biopsy. The infant made full recovery on supportive treatment during a one year follow up period.

CASE REPORT

A male infant was brought by his parents at the age of 4 weeks because of yellow discoloration of skin and sclera which started in the second week of life. The infant was born at term, pregnancy was uneventful and his birth weight was 2.6 kg. He was fully breast fed, his urine had deep yellow colour and stool was of normal colour. There was no consanguinity and no family history of neonatal jaundice. Clinical examination revealed a well baby who was deeply jaundiced and was thriving well. The baby was not dysmorphic and had normal vital signs. Abdominal examination revealed hepatomegaly of 4 cm with liver span of 10 cm.

His initial full blood count was normal. Liver function tests showed total serum bilirubin of 30 mg/dl, direct bilirubin of 21mg/dl, aspartate aminotransferase (AST) 583 U/L, alanine aminotransferase (ALT) 359 U/L, total protein 5.4 g/dl, albumin 3.9 g/dl, and alkaline phosphatase 450 U/L. Prothrombin time (PT), activated partial thromboplastin time (APTT) and renal function tests were all normal. Urine for reducing substances was negative as well as urine culture and sensitivity. Hepatitis B and C screening was negative, TORCH IgM screening was also negative. Abdominal ultrasound showed enlarged liver with normal texture and echogenicity, no focal lesion, normal gall bladder, no intra or extra hepatic biliary ducts dilatation. It also showed normal spleen, pancreas, and urinary bladder, and no ascites.

As the above tests were inconclusive a HIDA scan was obtained which showed intense homogeneous tracer uptake in the liver with no excretion into the duodenum and bowel in the dynamic images as well as the 2 hour and 24 hour images, which was highly suggestive of EHBA (Figure 1).

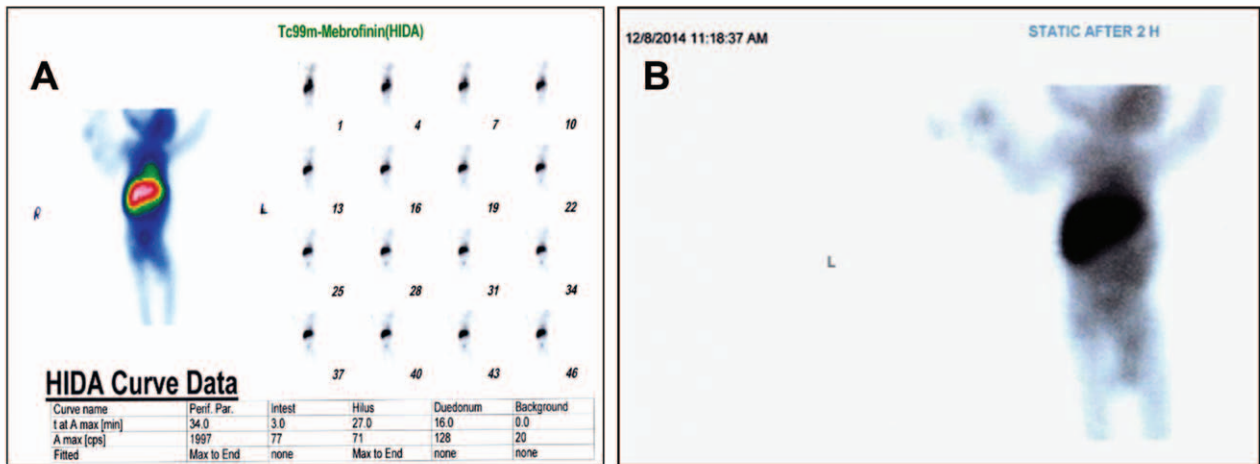


Figure 1 - Hepatobiliary iminodiacetic acid (HIDA) scan showed intense homogeneous tracer uptake in the liver with no excretion into the duodenum and bowel in the dynamic images (A) as well as the 2 hour image (B).

After consultation with the paediatric surgeon, a percutaneous liver biopsy was obtained which showed foamy degeneration of hepatocytes, giant cell transformation, prominent bile stasis and moderate

mixed inflammatory cellular infiltrate in the portal tract with piece meal necrosis which was consistent with giant cell neonatal hepatitis (Figures 2 and 3).

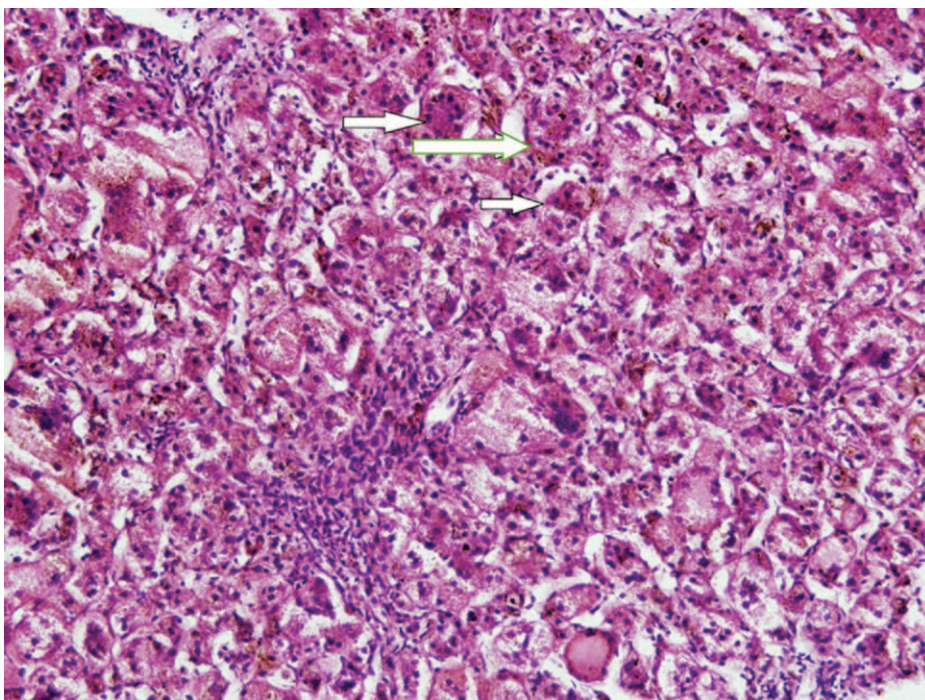


Figure 2 - Liver biopsy showing giant cells (arrows).

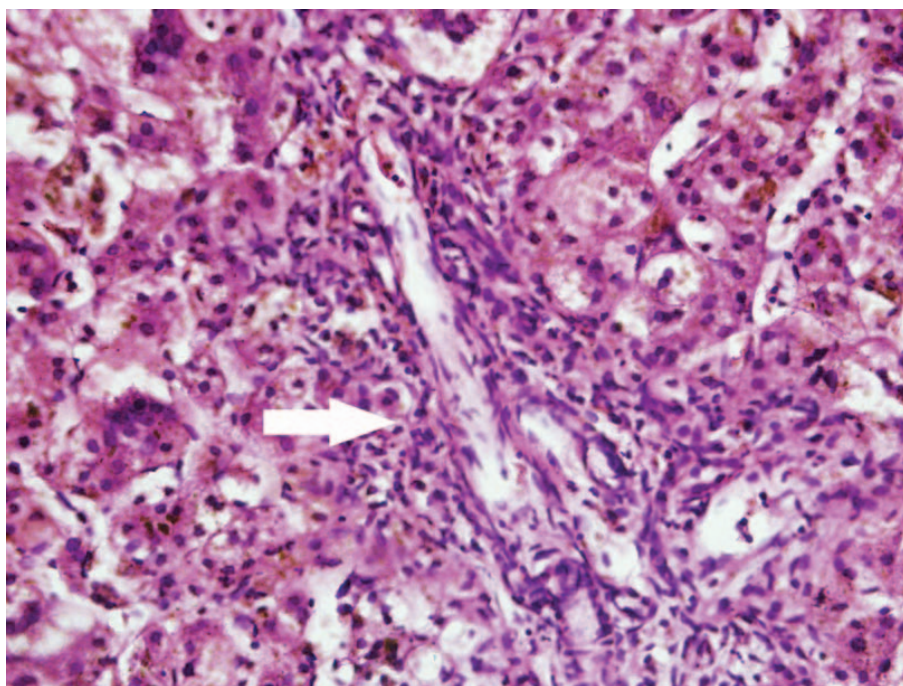


Figure 3 - Liver biopsy showing mixed inflammatory cells in the portal tract (arrow).

The baby was commenced on fat soluble vitamins (A, D, E and K), ursodeoxycholic acid, zinc sulphate and multivitamin syrup. The baby started to show gradual improvement in his liver profile, remained stable and maintained normal synthetic liver function tests. He was discharged home after 8 weeks with liver function that showed total serum bilirubin of 14.9 mg/dl and direct bilirubin of 11.3 mg/dl, AST 340 U/L, ALT 219 U/L, alkaline phosphatase 356 U/L, total protein 5g/dl and albumin 3.8 g/dl. The baby was regularly reviewed in the outpatient clinic and when he was seen very recently at the age of one year, he was thriving well with normal development. The most recent liver function test was entirely normal (total protein 4.6g/dl, albumin 3g/dl, AST 11 U/L, ALT 18 U/L, total serum bilirubin 0.7mg/dl, direct 0.6mg/dl, and alkaline phosphatase 150 U/L).

DISCUSSION

The incidence of neonatal cholestasis is approximately 1 in 2,500 live births. The two most common conditions that accounts for two third of the cases of

neonatal cholestasis are EHBA and INH [6].

It is not usually possible to distinguish between INH and EHBA on clinical or laboratory grounds. Hence liver biopsy might be the only discriminating investigation [7]. In our case, liver biopsy played a critical role in diagnosis. Initially HIDA scan favoured the diagnosis of EHBA, however, it is known that HIDA scan has both sensitivity and specificity issues. Our case received phenobarbitone prior to the scan which is known to stimulate the hepatic enzymes and increase the bile flow but yet the test was not conclusive. Many ways have been suggested to enhance the sensitivity and specificity of HIDA scan including the use of phenobarbitone and betamethasone prior to HIDA scan [8].

Idiopathic neonatal hepatitis (INH) is more common in males, small for dates and premature neonates [9]. Our case with INH was a male but he was full term and was not small for dates. Two categories of idiopathic neonatal hepatitis have been identified, the familial and the nonfamilial or sporadic type [10]. Based on this, our case falls into the sporadic category, which explains the good outcome; as the familial form

carries a poor prognosis and is usually associated with an underlying bile acid metabolism disorder [11].

The overall prognosis of INH is generally good with more than 90 % clinical and biochemical recovery by one year of age [12]. Although different studies have shown different mortality rates, Danks et al reported a 30% overall mortality in the first year of life [13]. Other studies showed a better outcome with mortality rate ranging from 6.5% to 12.9% [14]. Our case had an excellent outcome and full recovery by the end of the first year of life. He didn't show any of the poor prognostic associations such as acholic stools, severe jaundice beyond six months of age, persistent hepatomegaly and/or positive family history [14].

CONCLUSION

Idiopathic neonatal hepatitis is a diagnosis attained by excluding all other causes of neonatal hepatitis. It should be included in the differential diagnosis of infants with prolonged obstructive jaundice. Liver biopsy is the most reliable method to differentiate INH from EHBA.

ACKNOWLEDGEMENTS

We would like to thank the family of the baby mentioned in this report for consenting to publish their child's case. Thanks are also extended to the staff of the Histopathology Laboratory at Soba University Hospital.

REFERENCES

1. Kelly DA. Disease of the liver and biliary system in children. Edinburgh: Blackwell Science. London, 1999; 21-22
2. Ghishan FK, LaBrecque DR, Mitros FA, Younoszai MK. The evolving nature of "infantile obstructive cholangiopathy". *J Pediatr* 1980; 97:27-32.
3. Roberts EA. Neonatal hepatitis syndrome. *Semin Neonatol.* 2003; 8(5):357-74.
4. Lough J, Metrakos JD. Idiopathic Neonatal Hepatitis, Discordance in Monozygotic Twins. *Can Med Assoc J* 1967; 96(18): 1258–1261.
5. Nishinomiya F, Abukawa D, Takada G, Tazawa Y. Relationships between clinical and histological profiles of non-familial idiopathic neonatal hepatitis. *Acta Paediatr Jpn* 1996; 38(3):242–247.
6. De Bruyne R, Van Biervliet S, Vande Velde S, Van Winckel M. Clinical practice: neonatal cholestasis. *Eur J Pediatr* 2011; 170(3):279–284.
7. Giriyan S, Marathe A. Idiopathic Neonatal Hepatitis- A Case Report, *Global journal for research analysis* 2015; (4) 9:13-14
8. Sinha CK, Davenport M. Biliary atresia. *J Indian Assoc Pediatr Surg.* 2008; 13(2): 49–56
9. Balisteri WF. Neonatal cholestasis: Lessons from the past, issues for the future. *Semin Liver Dis.* 1987 May; 7(2):61-6.
10. Lawson EE, Boggs JD. Long-term follow-up of neonatal hepatitis: safety and value of surgical exploration. *Pediatrics* 1974; 53(5):650-656.
11. Nishinomiya F, Abucawa D, Takada G, Tazawa Y. Relationships between clinical and histological profiles of nonfamilial idiopathic hepatitis. *Acta Paediatr Jpn* 1996; 38(3):242-247
12. McKiernan PJ. The infant with prolonged jaundice: investigation and management. *Curr Paediatr.* 2001; 11:83–89.
13. Danks DM, Campbell PE, Smith AI, Rogers J. Prognosis of babies with neonatal hepatitis. *Arch Dis Child* 1977; 52(5):368-372.
14. Smith AL, Danks DM, Campbell PE, Rogers JG. The prognosis of babies with neonatal hepatitis. In: M. Kasai, K. Shiraki, eds. *Cholestasis in infancy. Its pathogenesis, diagnosis and treatment.* Tokyo/Baltimore: University Park Press, 1980:317-323.