

## ORIGINAL ARTICLE

# Renal scarring following urinary tract infections in children

Balakrishna Bandari (1), Seema Pavaman Sindgikar (1), Soma Santosh Kumar (1), Mangalapady Shenoy Vijaya (1), Raghu Shankar (2)

(1) Department of Pediatrics, K. S. Hegde Medical Academy, Mangalore, NITTE University, Mangalore, India

(2) Department of Pediatric Surgery, K. S. Hegde Medical Academy, Mangalore, NITTE University, Mangalore, India

## ABSTRACT

Urinary tract infection (UTI) is the most common bacterial infection seen in younger age group children. The most common risk factor for renal scarring in children with post-UTI is vesicoureteral reflux (VUR). This study looked at renal scarring following UTI in children by dimercaptosuccinic acid (DMSA) scan. It is a cross-sectional time bound study done among 40 infants and children with UTI for a period of 24 months. Their clinical presentation and laboratory data, including micturating cystourethrogram, were documented. DMSA scan, done during the follow-up, established the presence of renal scars if any. UTI was more common in males. Children with history of recurrent UTI had renal scarring. Statistical significance was noted when first and recurrent attacks of UTI were compared for clinical and diagnostic characteristics like *Escherichia coli* UTI ( $p = 0.007$ ), increasing grades of VUR ( $p = 0.006$ ) and renal scar formation ( $p = 0.041$ ). The study concluded that the high

grades of antenatal hydronephrosis (100%), febrile UTI (34%), younger age group (67.5%) and *E. coli* UTI (86%) were more associated with recurrent attacks of UTI and renal scarring. DMSA, being the non-invasive test, is better proven to be an investigation of choice than other invasive modalities for follow-up of children with recurrent attacks of UTI.

## KEYWORDS

Renal scar; Dimercaptosuccinic acid scan; *Escherichia coli*; Hydronephrosis; Vesicoureteric reflux.

## INTRODUCTION

Urinary tract infection (UTI) is the most common bacterial infection seen in younger age group, *Escherichia coli* being the frequently isolated organism [1]. UTI is defined as the presence of a pure bacterial growth of single species more than  $10^5$  colony-forming units (cfu) per millilitre of urine. Recurrent UTI is defined as three or more

## Correspondence to:

Seema Pavaman Sindgikar  
Associate Professor, Department of Pediatrics,  
K. S. Hegde Medical Academy, NITTE  
University, Mangalore, India  
Email: seemapavaman@nitte.edu.in

Received: 09 April 2019 | Accepted: 22 April 2019

## How to cite this article:

Bandari B, Sindgikar SP, Kumar SS, Vijaya MS, Shankar R. Renal scarring following urinary tract infections in children. Sudan J Paediatr. 2019;19(1):25–30.  
<https://doi.org/10.24911/SJP.106-1554791193>

episodes of UTI with cystitis/lower UTI [2]. In a male infant, an attack of UTI and its recurrence warrants urogenital evaluation for congenital abnormalities. Analysis of such urinary infections includes urine culture sensitivity, ultrasonography (US), micturating cystourethrogram (MCUG), cystoscopy and dimercaptosuccinic acid (DMSA) renal scan for a complete evaluation. Renal scarring following an attack of UTI can be diagnosed by DMSA scan, which is the gold standard [3]. Generally, during the first attack of UTI, the formation of renal scarring is absent to minimal in the absence of coexisting anomalies [4]. However, there are studies which have reported renal scarring even after first febrile UTI [5]. MCUG is an invasive procedure for the diagnosis of vesicoureteral reflux (VUR). Renal scarring generally correlates with severe grade of VUR [6,7]. Prenatal ultrasonograms can detect urogenital anomalies and such neonates can be followed up for the presence of VUR. In the absence of anomaly, VUR can be missed, until, and unless, there is an episode of UTI. DMSA, as a non-invasive modality to test the renal parenchymal involvement, can be included to detect renal scars during follow-up of infants after the first attack of UTI. Such children also need follow-up for development of hypertension, proteinuria and end-stage renal disease. Hence, this study was carried out to look for renal scarring tendencies in children who had UTI.

## MATERIALS AND METHODS

This was a cross-sectional time-bound study done in tertiary care centre, over a period of 2 years. Infants and children less than 13 years who presented as out or inpatient in the Departments of Pediatrics and Pediatric Surgery with the diagnosis of culture-positive UTI were included. Clinical presentation of urinary manifestations like dysuria, increased frequency of micturition, urgency with or without fever were evaluated for UTI. Urine sample was collected in a sterile urine collection bag in younger children <2 years of age after disinfecting the perineum and as midstream clean catch sample in >2 years of age [2]. They were classified to have either first or recurrent

episodes. A detailed history of clinical features suggesting UTI, including antenatal history if any, systemic examination and lab data were documented in a structured questionnaire. Blood pressure (BP) was recorded using appropriate sized cuff. Hypertension is defined as average systolic BP and/or diastolic BP that is greater than or equal to the 95th percentile for gender, age and height on three or more occasions [8]. Investigations included renal function tests (urea and creatinine), routine urinalysis and microscopy, urine culture and sensitivity and ultrasound abdomen at the time of presentation. The diagnosis was confirmed by proven positive urine culture test of  $>10^5$  cfu/ml as per the NICE guidelines [2]. During follow-up between 3 and 6 months MCUG, cystoscopy (as indicated) and DMSA scans were performed. US abnormalities were documented by a consultant radiologist. VUR grading was done after MCUG procedure as per the standards [9]. DMSA scan was done by nuclear medicine specialist. Renal scars were identified and graded as per the standard classification [10]. The types were classified as type 1: no more than two scars, type 2: more than two scars with some normal parenchyma between them, type 3: generalized damage to the whole kidney and type 4: end stage "shrunken" (kidney with little or no uptake of DMSA, i.e.,  $<10\%$  of the overall function). Those with existing renal diseases, such as chronic kidney disease, acute kidney injury and UTI following urethral catheterization and surgical procedures were excluded from the study. Ethical clearance and approval of the study were granted by the Institutional Ethics Committee. Signed informed consent for participation and publication of medical details were obtained from the parents. Confidentiality was ensured at all the stages.

Statistical analysis was performed using software packages SPSS 22.0. The data are expressed as numbers and percentages ( $n\%$ ). Bar charts are used to display percentages for categorized variables. Chi-square test was used to find the significance of association between categorized variables for inferential statistics wherein  $p$ -value of  $<0.05$  was taken significant.

## RESULTS

A total of 40 children with culture-positive UTI were included. The higher occurrence of UTI was in males (male to female ratio 2.6:1). Circumcision was done in seven children. First attack of UTI was observed in 23 (57.5%) children. The occurrence of UTI was more in younger age (<1 year: 12.5%; <5 years: 67.5%). Female children had more incidence of recurrent UTI (54.5%). Clinical features and laboratory data are tabulated in Table 1. Fever was not the presenting feature in 20%, but irritability, dysuria, vomiting and constipation were pointers to diagnose UTI. Prenatal US, as part of anomaly scan, was abnormal for genitourinary system in 11 (27.5%) children. Out of these children, three cases had renal scarring after the first attack of UTI. Moderate-to-severe hydronephrosis (HUN) was the common finding observed. Most predominant organism cultured was *E. coli*, others were *Klebsiella*, *Proteus*, *Pseudomonas*, *Enterococci*, *Citrobacter* and *Staphylococcus aureus*. During an episode of UTI, 27 children had US abnormalities. The abnormalities noted were hydronephrosis (27.5%), cystitis (12.5%), posterior urethral valve (PUV) (10%), pyelonephritis (10%), pelvi-ureteric junction abnormalities (5%), left duplex kidney (2.5%) and right solitary kidney (2.5%).

These findings were more seen in recurrent UTI (82.4%). Positive reflux was noted in 23 cases, majority in recurrent UTI (82.4%). Grade 5 VUR was present in five children. Five children with constipation were noted to have Grade 1 VUR, amounting to secondary VUR.

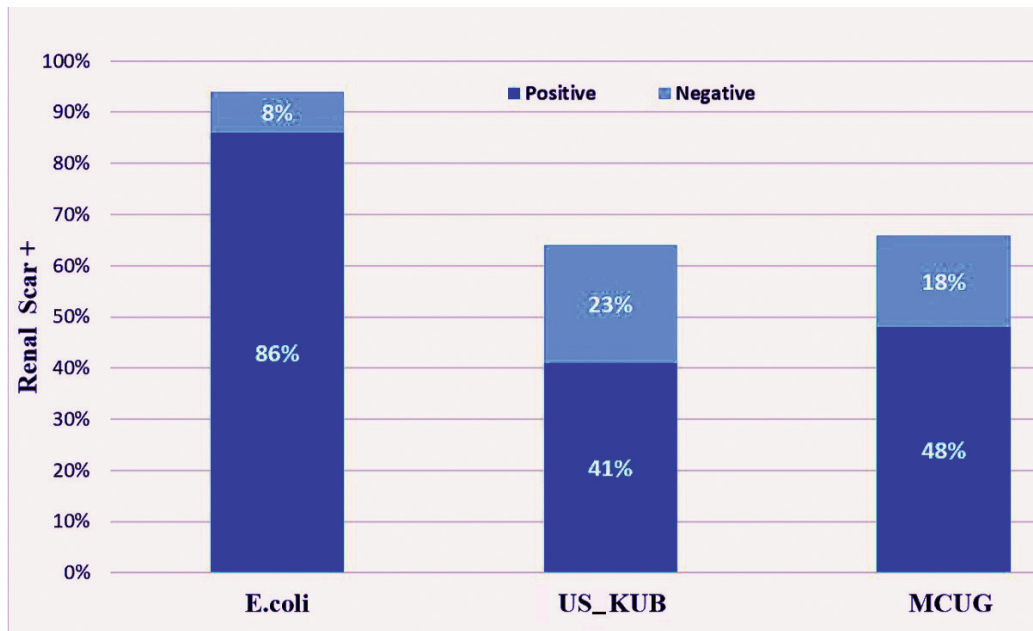
All the children underwent DMSA scan during the follow-up period. The significance of *E. coli* UTI, US abnormalities, positive VUR and renal scarring comparison between first and recurrent attacks is shown in Table 2. The significance was noted for all except US. Renal scars were present in 14 children, 21.7% in the first episode of UTI. Scarring was more common in males (78.5%). Febrile UTI had more risk of scarring (34.3%). Among the *E. coli* UTI, scarring was observed in 86% of cases (Figure 1). All the children with abnormal prenatal US of moderate-to-severe HUN had renal scarring during the follow-up. DMSA scan was abnormal in three children (23%) with normal US findings. Two of them had recurrent UTI and one child was diagnosed with pyelonephritis (*S. aureus* UTI). Positive VUR contributed to 47.8% of renal scarring. Renal scar was formed in four children who had Grade 5 VUR. During the first attack of UTI, nine (39%) children had positive reflux and three (33%) among them had renal scarring. These children were diagnosed to have posterior urethral valve. In absence of reflux,

**Table 1.** Clinical features and laboratory data.

Clinical features	Number (%)	Investigations	Number (%)
Symptoms		<i>E. coli</i>	14 (35%)
Fever	31 (78%)	Abnormal US	27 (67.5%)
Vomiting	5 (12.5%)	VUR Positive	23 (57.5%)
Dysuria	24 (60%)	VUR Absent	17 (42.5%)
Frequency	10 (25%)	Grade 1 VUR	6 (15%)
Poor feeding	12 (30%)	Grade 2 VUR	3 (7.5%)
Constipation	12 (30%)	Grade 3 VUR	5 (12.5%)
Hypertension	4 (10%)	Grade 4 VUR	4 (10%)
		Grade 5 VUR	5 (12.5%)
		Renal scar present (DMSA)	14 (35%)
		Type 1	8 (57.1%)
		Type 2	5 (35.7%)
		Type 3	1 (7.14%)
		Type 4	0

**Table 2.** Comparison of *Escherichia coli* UTI, abnormal US, positive MCUG and DMSA scan with first and recurrent attacks of UTI.

Characteristics	First attack	Recurrent attack	p value
<i>Escherichia coli</i> UTI	4 (17.4%)	10 (58.8%)	0.007
Abnormal US	13 (56.5%)	14 (82.4%)	0.085
Positive MCUG	9 (39.1%)	14 (82.4%)	0.006
Renal scar (DMSA scan)	5 (21.7%)	9 (52.9%)	0.041



**Figure 1.** Bar diagram representing the relation between renal scarring and *E. coli* and non *E. coli* UTI, MCUG, and US kidneys, ureters and bladder (KUB).

type 1 renal scar was formed in three children during the follow-up, probably because of recurrent attacks.

## DISCUSSION

This study was done with the intention to assess renal scarring tendency in children who also have underlying genitourinary abnormalities. Younger children are more prone to develop scarring. Several studies report that renal scars are common in younger age (less than 2 years) of onset for UTI [10]. NICE guidelines recommend that male infants and children with recurrent UTI need to be worked for any renal malformations and need a close follow-up. Atypical UTI and recurrent UTI need to be worked up with an US

during an episode of acute infection, DMSA 4–6 months and MCUG following the acute event [2].

Fever and dysuria were common clinical manifestations. Afebrile UTI can also have scar formation if associated anomalies are present [11]. Our study reports 38% afebrile UTI had scarring. Najib et al. [4] reports that between febrile and afebrile UTI, scar formation was more with the former (43.7% and 13.5%). Recurrent attacks of UTI had underlying predisposing factors like constipation, VUR as reported in the literature [12]. Many paediatric studies support that 85%–90% of urine culture isolate is *E. coli* and has more risk of scarring similar to our study [1,13]. Antenatal scans positive for renal anomalies are prone to develop UTI and consequences in postnatal life. All the children (100%) diagnosed

with moderate-to-severe grade HUN in utero had renal scarring. The literature suggests increasing grades of HUN is associated with increased risk of urologic pathologies [14]. Gökaslan et al. [15] reports statistically significant ( $p = 0.005$ ) correlation between the anomalous prenatal scan and scar formation postnatally. In the present study, cortical scarring was noted in children with posterior urethral valves with VUR, even after the first attack of UTI. Freitas AC et al reports scarring can be seen in 20% of cases after the first episode [16]. Without evidence of VUR, renal scarring can be seen with specific conditions. Shaikh et al. [17] reports 18% of cases had evidence of scar formation without VUR secondary to haematological spread of organisms. In our study, the haematological spread of *S. aureus* infection and renal anomalies were predisposing conditions in 17.6% cases in the absence of VUR. Statistical significance was noted when first and recurrent attacks of UTI were compared for clinical and diagnostic characteristics, such as *E. coli* UTI ( $p = 0.007$ ), increasing grades of VUR ( $p = 0.006$ ) and renal scar formation ( $p = 0.041$ ). Mir et al. [18] and Snodgrass et al. [19] report that there is increased incidence of UTI among children with VUR as major risk factor for recurrent UTI. The reason behind VUR to cause recurrent UTI was because it elevates bladder pressure which gets transmitted to the kidney causing reflux nephropathy and scar formation. This study had shown 33%, 33%, 40%, 50% and 80% of renal scarring in children with Grades I, II, III, IV, and V respectively ( $p \geq 0.05$ , not significant statistically). Similar to this, a study proved that increasing grades of VUR has greater chances of renal scarring, i.e., 0%, 30.7%, 50%, 69.5% and 100% in Grades I, II, III, IV and V, respectively ( $p = 0.001$ ) [20].

## CONCLUSIONS

Recurrent UTI is relatively common in young children. Antenatal HUN (high grades), febrile UTI, female gender, children less than 5 years age group, congenital abnormalities (PUV and duplex kidney), increasing grades of VUR, infection with uropathogenic *E. coli* were the common risk factors associated with recurrent UTI and renal

scarring in this study. Hence, the management of children with recurrent UTI depends on the age of presentation and the severity of associated symptom. We also recommend DMSA scan to evaluate children with first episode of UTI who were diagnosed to have high grade HUN by prenatal US, and in recurrent UTI, especially younger age group. Long-term follow-up of these children has to be done for the identification of complications such as renal function deterioration and hypertension. Our study also suggests that incidence of renal scarring was high in recurrent UTI and that absence of VUR is not protective, as renal scarring can occur even without VUR. Early diagnosis and aggressive treatment of these children is required.

## CONFLICTS OF INTEREST

None.

## FUNDING

None.

## ETHICS

Ethical clearance and approval of the study were granted by the Institutional Ethics Committee. Signed informed consent for participation and publication of medical details were obtained from the parents. Confidentiality was ensured at all stages.

## REFERENCES

1. Kunin CM. Epidemiology and natural history of urinary tract infection in school age children. *Pediatr Clin North Am.* 1971;18:509–28. [https://doi.org/10.1016/S0031-3955\(16\)32563-9](https://doi.org/10.1016/S0031-3955(16)32563-9)
2. National Collaborating Centre for Women's and Children's Health (Great Britain), Royal College of Obstetricians and Gynaecologists (Great Britain). *Urinary tract infection in children: diagnosis, treatment, and long-term management.* London, UK: RCOG Press; 2007.
3. Hains DS, Cohen HL, McCarville MB, Ellison EE, Huffman A, Glass S, et al. Elucidation of renal scars in children with vesicoureteral reflux using contrast-enhanced ultrasound: a pilot study. *Kidney Int Rep.* 2017;2(3):420–4. <https://doi.org/10.1016/j.ekir.2017.01.008>



4. Najib KH, Fallahzadeh E, Fallahzadeh MK, Fallahzadeh MH, Erjaee A. Renal scar formation in children with recurrent urinary tract infections. *Iran Red Crescent Med J.* 2009;11(1):93–5.
5. Hoberman A, Charron M, Hickey RW, Baskin M, Kearney DH, Wald ER. Imaging studies after a first febrile urinary tract infection in young children. *N Engl J Med.* 2003;348(3):195–202. <https://doi.org/10.1056/NEJMoa021698>
6. Orellana P, Baquedano P, Rangarajan V, Zhao JH, Eng ND, Fettich J, et al. Relationship between acute pyelonephritis, renal scarring, and vesicoureteral reflux: results of a coordinated research project. *Pediatr Nephrol.* 2004;19:1122–6. <https://doi.org/10.1007/s00467-004-1501-5>
7. Zaffanello M, Cataldi L, Brugnara M, Franchini M, Bruno C, Fanos V. Hidden high-grade vesicoureteral reflux is the main risk factor for chronic renal damage in children under the age of two years with first urinary tract infection. *Scand J Urol Nephrol.* 2009;43:494–500. <https://doi.org/10.3109/00365590903286663>
8. National High Blood Pressure Education Program Working Group on High Blood Pressure in Children and Adolescents. The fourth report on the diagnosis, evaluation, and treatment of high blood pressure in children and adolescents. *Pediatrics.* 2004;114:555–76. <https://doi.org/10.1542/peds.114.2.S2.555>
9. Çelebi S, Özaydın S, Baştaş CB, Kuzdan Ö, Erdoğan C, Yazıcı M, et al. Reliability of the grading system for voiding cystourethrograms in the management of vesicoureteral reflux: an interrater comparison. *Adv Urol.* 2016;2016:1684190. <https://doi.org/10.1155/2016/1684190>
10. Beiraghdar F, Panahi Y, Einollahi B, Moharamzad Y, Nemati E, Amirsalari S. Predisposing factors for renal scarring in children with urinary tract infection. *Saudi J Kidney Dis Transplant.* 2012;23(3):532–37.
11. Hiraoka M. Medical management of congenital anomalies of the kidney and urinary tract. *Pediatr Int.* 2003;45(5):624–33.
12. Keren R, Shaikh N, Pohl H, Gravens-Mueller L, Ivanova A, Zaoutis L, et al. Risk factors for recurrent urinary tract infection and renal scarring. *Pediatrics.* 2015;136(1):e13–21. <https://doi.org/10.1542/peds.2015-0409>
13. Conover MS, Hadjifrangiskou M, Palermo JJ, Hibbing ME, Dodson KW, Hultgren SJ. Metabolic requirements of *Escherichia coli* in intracellular bacterial communities during urinary tract infection pathogenesis. *mBio.* 2016;7(2):1–13. <https://doi.org/10.1128/mBio.00104-16>
14. Ylinen E, Ala-Houhala M, Wikström S. Risk of renal scarring in vesicoureteral reflux detected either antenatally or during the neonatal period. *Urology.* 2003;61(6):1238–42. [https://doi.org/10.1016/S0090-4295\(03\)00229-2](https://doi.org/10.1016/S0090-4295(03)00229-2)
15. Gökaslan F, Yalçinkaya F, Fitöz S, Özçakar ZB. Evaluation and outcome of antenatal hydronephrosis: a prospective study. *Renal Failure.* 2012;34(6):718–21. <https://doi.org/10.3109/0886022X.2012.676492>
16. Freitas AC, Leite J, Matos P, Rocha L, Costa T, Faria S, et al. Risk factors for renal scarring after first febrile urinary tract infection. *Nascer e Crescer.* 2016;25(1):11–4.
17. Shaikh N, Ewing AL, Bhatnagar S, Hoberman A. Risk of renal scarring in children with a first urinary tract infection: a systematic review. *Pediatrics.* 2010;126(6):1084–91. <https://doi.org/10.1542/peds.2010-0685>
18. Mir S, Ertan P, Ozkayin N. Risk factors for renal scarring in children with primary vesicoureteral reflux disease. *Saudi J Kidney Dis Transplant.* 2013;24(1):54–9. <https://doi.org/10.4103/1319-2442.106241>
19. Snodgrass WT, Shah A, Yang M, Kwon J, Villanueva C, Traylor J, et al. Prevalence and risk factors for renal scars in children with febrile UTI and/or VUR. *J Pediatr Urol.* 2013;9(6):856–63. <https://doi.org/10.1016/j.jpuro.2012.11.019>
20. Park YS. Renal scar formation after urinary tract infection in children. *Korean J Pediatr.* 2012;55(10):367–70. <https://doi.org/10.3345/kjp.2012.55.10.367>