

## CASE REPORT

# Pulmonary arteriovenous malformation in a neonate: a condition commonly misdiagnosed

Mohammed H. A. Mohammed (1,2), Abdah Hrfi (1), Abdullah M. AlQwee (3), Omar Tamimi (1,4)

(1) Cardiac Sciences Department, King Abdulaziz Cardiac Center, National Guard Health Affairs, Riyadh, Kingdom of Saudi Arabia

(2) Department of Pediatrics, Faculty of Medicine, Omdurman Islamic University, Khartoum, Sudan

(3) Prince Sultan Cardiac Center, Qassim, Kingdom of Saudi Arabia

(4) King Saud Bin Abdulaziz University for Health Sciences, Riyadh, Saudi Arabia

### ABSTRACT

Pulmonary arteriovenous malformations (PAVMs) are congenital defects in the form of an anomalous bridging between a pulmonary arterial and venous system that sidesteps the normal pulmonary capillary. This anomaly is usually associated with hereditary hemorrhagic telangiectasia, leftover small group are sporadic cases but may occur as an isolated anomaly or as multiple lesions. Rarely, such abnormalities can be acquired. Few cases are diagnosed in the neonatal period, as it will pass silent without symptoms. Clinical manifestations occur soon after birth as cyanosis, tachypnea, and an abnormal sound as bruit over the AVM; and the most important point is the clinical suspicion of diagnosis in absence of pulmonary parenchymal and cardiac disease that can explain the persistence of cyanosis. We report a successful Amplatzer vascular plug occlusion of isolated multiple left side PAVM in a neonate, which was done on two stages with a 6 months interval, with no complications. Over 2-year follow-up, the patient remained well with no symptoms.

### KEYWORDS:

Pulmonary arteriovenous malformation; Transcatheter; Amplatzer; Newborn.

### INTRODUCTION

Pulmonary arteriovenous malformations (PAVMs) are congenital defects in the form of an anomalous bridging between pulmonary arterial and venous systems that sidesteps the normal pulmonary capillary bed [1]. It has been the first time mentioned as incidental findings during the autopsy of a young man by Churton [2], while the first patient labeled to have PAVM was in 1939. The majority of cases (80%–90%) with PAVM are associated with hereditary hemorrhagic telangiectasia, leftover small group are sporadic cases [3]. The greatest number of PAVM cases affects one side and may be found at any segment of the lung, but generally in the lower lobes [3]. In a patient with mysterious cyanosis without pulmonary parenchymal or cardiac diseases, PAVM should be suspected.

### Correspondence to:

Omar Tamimi,  
Pediatric Cardiology Interventionist,  
King Abdulaziz Cardiac Center, Riyadh 11426,  
Saudi Arabia. Email: drtamimi@hotmail.com

Received: 04 June 2018 | Accepted: 11 December 2018

### How to cite this article:

Mohammed HA, Hrfi A, Algwee A, Tamimi O. Pulmonary arteriovenous malformation in a neonate: a condition commonly misdiagnosed. Sudan J Paediatr. 2018;18(2):56–60.

<https://doi.org/10.24911/SJP.106-1528143670>

Serial arterial blood gas analysis will exhibit a failure to attain a normal arterial saturation. Chest X-ray is one of the diagnostic clues by showing solitary or multiple round lesions in most cases, but patients with microvascular telangiectasia may have normal chest X-ray [4]. Contrast computed tomography can establish the presence of AVMs; and nuclear studies, including technetium perfusion scans with labeled albumin macroaggregates, have been used to measure the degree of right-to-left shunting [5]. Contrast echocardiography is often used to make the diagnosis [6]. Pulmonary angiography will show directly the presence, the degree of PAVM, and can be used in suitable situations for management [7]. Until 1977, surgery was known as the only treatment for patients with PAVM; and involved string of PAVM, local excision, segmentectomy, lobectomy, and even pneumonectomy [8]. Following that, management alternatives for PAVM, such as transcatheter embolization with coil occlusion and Amplatzer vascular plugs, were also used [9]. PAVM resolution after embolization leads to decreased right-to-left shunting and improved oxygenation [10]. PAVM occlusion has been shown to reduce the risk of ischemic stroke [11]. In some cases, the persistence of the AVM even with embolization has been reported [12]. Also, recanalization of the artery or growth of accessory vessels to the PAVM can happen [13].

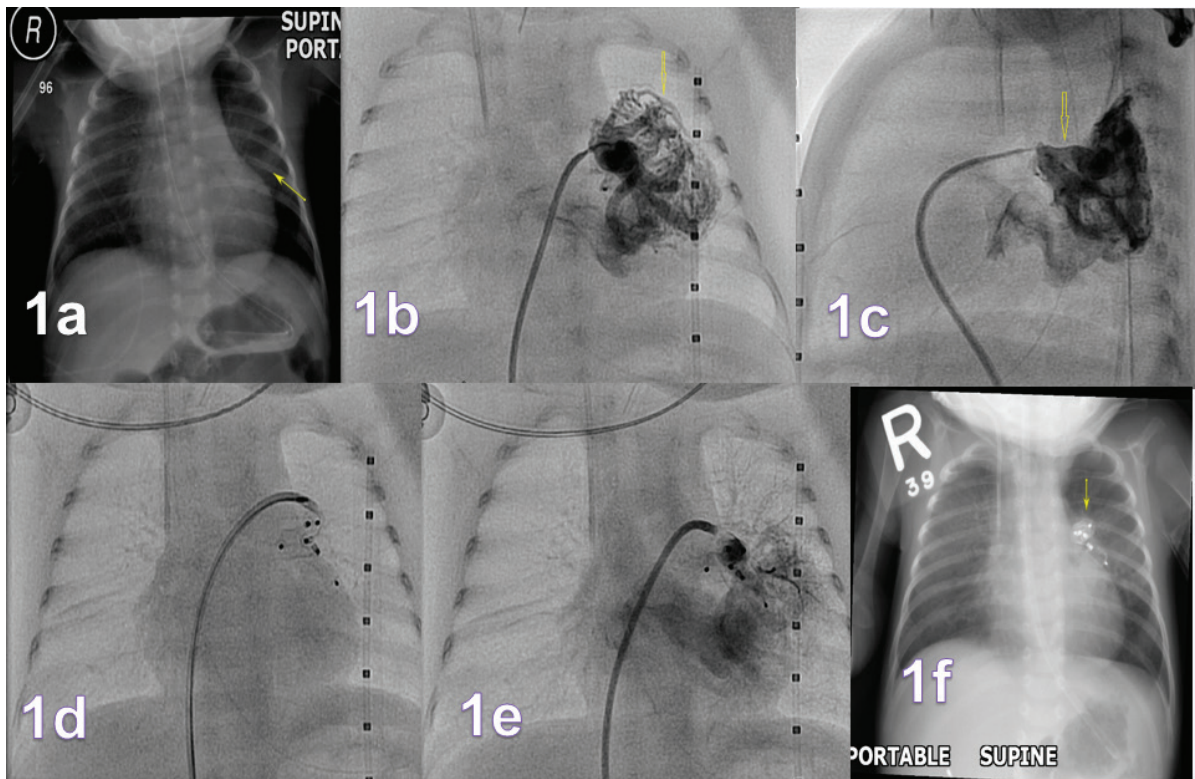
## CASE REPORT

A 2-year-old boy, preterm of 34 weeks-gestation, product of emergency cesarean section and delivered at a private hospital, birth weight 2 kg, with unremarkable pregnancy period, developed respiratory distress with cyanosis immediately after birth. For this reason, he was admitted to the Neonatal Intensive Care Unit. Cardiovascular examination was unremarkable apart from grade 2 systolic murmur at the upper left sternal border, and chest examination revealed normal bilateral vesicular breathing. Examination of the abdomen, central nervous system, skin, and mucosa did not reveal any other abnormality. He was connected to mechanical ventilator due to persistent hypoxia with oxygen saturation between 60% and 70% in 100% of the fraction of inspired oxygen

( $\text{FiO}_2$ ). He was treated for neonatal sepsis, neonatal jaundice, thrombocytopenia, and neonatal convulsion; but despite a complete course of treatment and resolution of these, the baby still remained hypoxic with persistent low oxygen saturation. Head ultrasound was normal. The initial and repeated chest X-ray showed (Figure 1a) lobulated opacity in the left mid zone, which was treated as pneumonia.

Echocardiogram showed patent foramen ovale with a left to right shunt, right pulmonary artery smaller than left pulmonary arteries, increased flow in left lower pulmonary veins, and small aorta pulmonary collateral. After 5 weeks of failed mechanical ventilator extubation and low oxygen saturation in 100% of  $\text{FiO}_2$ , the patient was referred to our center (King Abdulaziz Cardiac Center, Riyadh, Saudi Arabia) for opinion and management. Investigations done at the referring hospital were reviewed, PAVM was suspected and agitated saline contrast echocardiogram (bubble study) was positive for PAVM. The patient, at an age of 6 weeks, with a weight of 2 kg, underwent cardiac catheterization that showed normal pulmonary artery pressure. Angiography (Figure 1b and c) revealed multiple AVMs in the upper segments of the left lung lower lobe. Most of these were occluded (Figure 1d and e) with two devices ( $6 \times 7$  mm) and one ( $4 \times 7$  mm) Amplatzer vascular plug I device (St. Jude Medical, St. Paul, MN). Baseline saturation on  $\text{FiO}_2$  100% was 80%, and after PAVM closure, saturation improved to 88% with  $\text{FiO}_2$  30%. The patient managed to be extubated, and chest X-ray post procedure exhibited devices in the left lung (Figure 1f). He was discharged home after 4 days in the Pediatric Cardiac Intensive Care Unit and 5 days in the ward, in room air with the saturation of 80%–85%.

At the age of 7 months, the patient was admitted again electively for the next stage of PAVM occlusion. He was stable, doing fine, gained weight (6 kg), and saturation in room air was 80%–85%. He underwent cardiac catheterization for the second time which showed normal pulmonary artery pressure. The angiogram (Figure 2a and b) revealed no residual shunt from previous plugs devices, the remaining part of PAVM was occluded using five devices of Amplatzer vascular plug



**Figure 1** - (a) Chest X-ray showing lobulated opacity in the left mid zone (arrow). (b and c) Angiography revealed multiple AVMs in the upper segments of the left lung lower lobe, and most of these were occluded (d and e). (f) Chest X-ray post procedure exhibiting devices in the left lung (arrow).

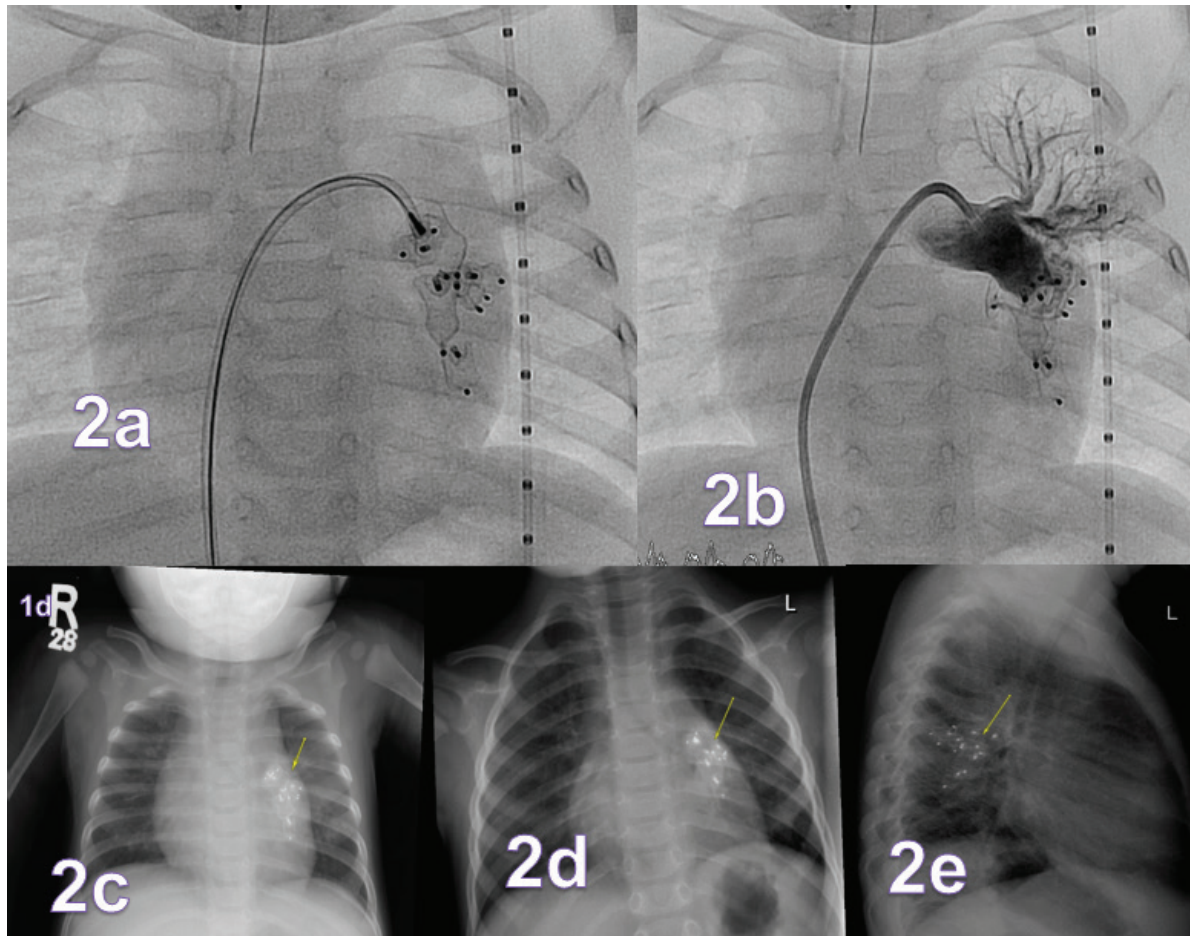
device I, two  $6 \times 7$ , one  $8 \times 7$ , another one  $10 \times 7$ , and one  $12 \times 8$  mm, with a minimal residual shunt at the end of the procedure. Saturation post occlusion significantly increased to 94% in room air. Chest X-ray (Figure 2c) after the procedure showed devices in the left lung.

The patient was discharged in stable condition and normal saturation. On follow-up visit at the age of 2 years, the patient was asymptomatic with no cyanosis, and saturation in room air was above 93%. Chest X-ray (Figure 2d and e) showed good left lung growth with good position of plug devices.

## DISCUSSION

Most of PAVM pass undiagnosed till adulthood period with only 10% of cases being noticed in childhood. The PAVM gender distribution is female to male ratio of 1.5–1.8:1 [14]. Other than being congenital, PAVM can occur as a result of trauma, malignancy, hepatopulmonary

syndrome in cirrhosis, and surgery. The PAVM change in size with time, puberty, and pregnancy, and pulmonary artery hypertension speeds up the process. The majority of PAVM are unilateral, occurring at any lung segment; however, lower lobes are most affected [3]. In our case, the final diagnosis was missed during the neonatal period, as the baby was treated as affected by pneumonia, and PAVM diagnosis has not been considered leading to delayed intervention. We considered staging closure due to the patient's weight which precluded adding more devices in such only 2 kg baby. Also, immediate improvement of oxygen saturation during PAVM occlusion reassured a good outcome at the first stage. Luckily, this management showed improvement and reduction of the complication rate in this patient. Missed diagnosis of these cases are not unusual, Aggarwal et al. [15] reported two cases, a 4-month-old and a neonate which were missed initially despite chest X-ray findings which were misinterpreted as pneumonia in one case and pulmonary hypertension in the other one. Both ended with



**Figure 2** - (a and b) Follow-up angiography at the age of 7 months revealed no residual shunt from previous plugs devices. (c) Chest X-ray after the remaining part of PAVM was occluded showing devices in the left lung (arrow). (d and e) Chest X-rays at the age of 2 years showed good left lung growth with good position of plug devices.

extracorporeal membrane oxygenation (ECMO) before a definitive diagnosis and appropriate intervention was made. This is, unfortunately, similar to what has happened to our case initially, but with no aggressive approach for hypoxia management.

## CONCLUSIONS

With successful PAVM percutaneous closure in most of the cases recently, delayed diagnosis or misinterpreting chest X-ray finding causes results in medical mismanagement of these cases. Normal heart structure and unspecific chest X-ray findings should raise the suspicion of PAVM for all health care providers before aggressive intervention for hypoxia is started.

## ACKNOWLEDGMENTS

Special thanks are due to our colleagues in the Pediatric Cardiac Intensive Care Unit, King Abdulaziz Medical City, Riyadh, Saudi Arabia, (not the neonatal).

## REFERENCES

1. Burke CM, Safai C, Nelson DP, Raffin TA. Pulmonary arteriovenous malformations: a critical update. *Am Rev Respir Dis.* 1986;134:334–9.
2. Churton T. Multiple aneurysm of pulmonary artery. *Br Med J (Clin Res Ed).* 1897;1:1223.
3. Lee EY, Boiselle PM, Cleveland RH. Multidetector CT evaluation of congenital lung anomalies. *Radiology.* 2008;247:632–48. <https://doi.org/10.1148/radiol.2473062124>

4. Gossage JR, Kanj G. Pulmonary arteriovenous malformations. A state-of-the-art review. *Am J Respir Crit Care Med.* 1998;158(2):643–61. <https://doi.org/10.1164/ajrccm.158.2.9711041>
5. Chilvers ER, Peters AM, George P. Quantification of right-to-left shunt through pulmonary arteriovenous malformations using Tc albumin microspheres. *Clin Radiol.* 1988;39:611–4. [https://doi.org/10.1016/S0009-9260\(88\)80065-5](https://doi.org/10.1016/S0009-9260(88)80065-5)
6. Claire L. Shovlin pulmonary arteriovenous malformations. *Am J Respir Crit Care Med.* 2014;190(11):1217–28. <https://doi.org/10.1164/rccm.201407-1254CI>
7. Borrero CG, Zajko AB. Pulmonary arteriovenous malformations: clinical features, diagnosis, and treatment. *J Radiol Nurs.* 2006;25:33–7. <https://doi.org/10.1016/j.jradnu.2006.04.011>
8. Burke CM, Safai C, Nelson DP, Raffin TA. Pulmonary arteriovenous malformations: a critical update. *Am Rev Respir Dis.* 1986;134:334–9.
9. Rabellino M, Serra M, Peralta O, Rodriguez P, Gentile E, Levy-Yayati E, et al. Early experience with the AMPLATZER vascular plug IV for the occlusion of pulmonary arteriovenous malformations. *J Vasc Interv Radiol.* 2014;25:1333–7. <https://doi.org/10.1016/j.jvir.2014.05.016>
10. Pierucci P, Murphy J, Henderson KJ, Chyun DA, White RI Jr. New definition and natural history of patients with diffuse pulmonary arteriovenous malformations: twenty-seven-year experience. *Chest.* 2008;133:653–61. <https://doi.org/10.1378/chest.07-1949>
11. Shovlin CL, Jackson JE, Bamford KB, Jenkins IH, Benjamin AR, Ramadan H, et al. Primary determinants of ischaemic stroke/brain abscess risks are independent of severity of pulmonary arteriovenous malformations in hereditary haemorrhagic telangiectasia. *Thorax.* 2008;63:259–66. <https://doi.org/10.1136/thx.2007.087452>
12. Woodward CS, Pyeritz RE, Chittams JL, Trerotola SO. Treated pulmonary arteriovenous malformations: patterns of persistence and associated retreatment success. *Radiology.* 2013;269:919–26. <https://doi.org/10.1148/radiol.13122153>
13. Lee DW, White RIJR, Egglin TK, Pollak JS, Fayad PB, Wirth JA, et al. Embolotherapy of large pulmonary arteriovenous malformations: long-term results. *Ann Thorac Surg.* 1997;64:930–9; discussion 939–40. [https://doi.org/10.1016/S0003-4975\(97\)00815-1](https://doi.org/10.1016/S0003-4975(97)00815-1)
14. Allen SW, Whitfield JM, Clarke DR, Sujansky E, Wiggins JW. Pulmonary arteriovenous malformation in the newborn: a familial case. *Pediatr Cardiol.* 1993;14:58–61.
15. Aggarwal V, Khan DM, Rhodes JF. Pulmonary arteriovenous malformation causing systemic hypoxemia in early infancy. *Case Rep Pediatr.* 2017;2017:1–5. <https://doi.org/10.1155/2017/2841720>